EBERHARD KARLS UNIVERSITÄT TÜBINGEN

Eberhard-Karls-Universität UKT Universitätsklinikum Tübingen

# Surgical complications of pediatric oncological surgery

Steven W. Warmann

Department of Pediatric Surgery and Pediatric Urology,
University Childrens Hospital, Tübingen, Germany

# Surgical approaches – complications?!

# Surgical approaches – complications?!

# Surgical approaches – complications?!

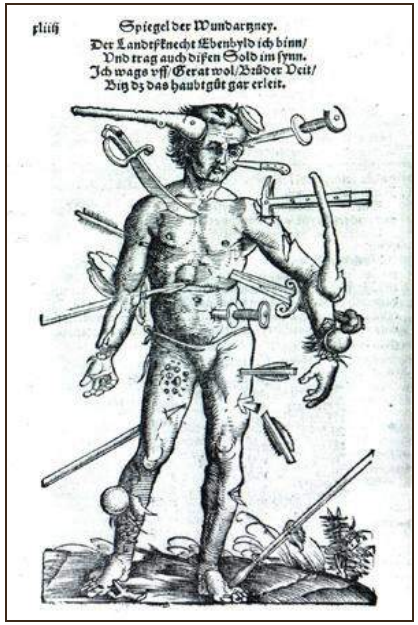

# Surgical approaches – complications?!

# Content

- Definition/Classification
- Selected entities
- Prevention
- Management strategies

# Classification of surgical complications

- Element of quality assessment
- Rarely used!, often only reseection status given
- Comparability of surgical procedures/results
- Definition!

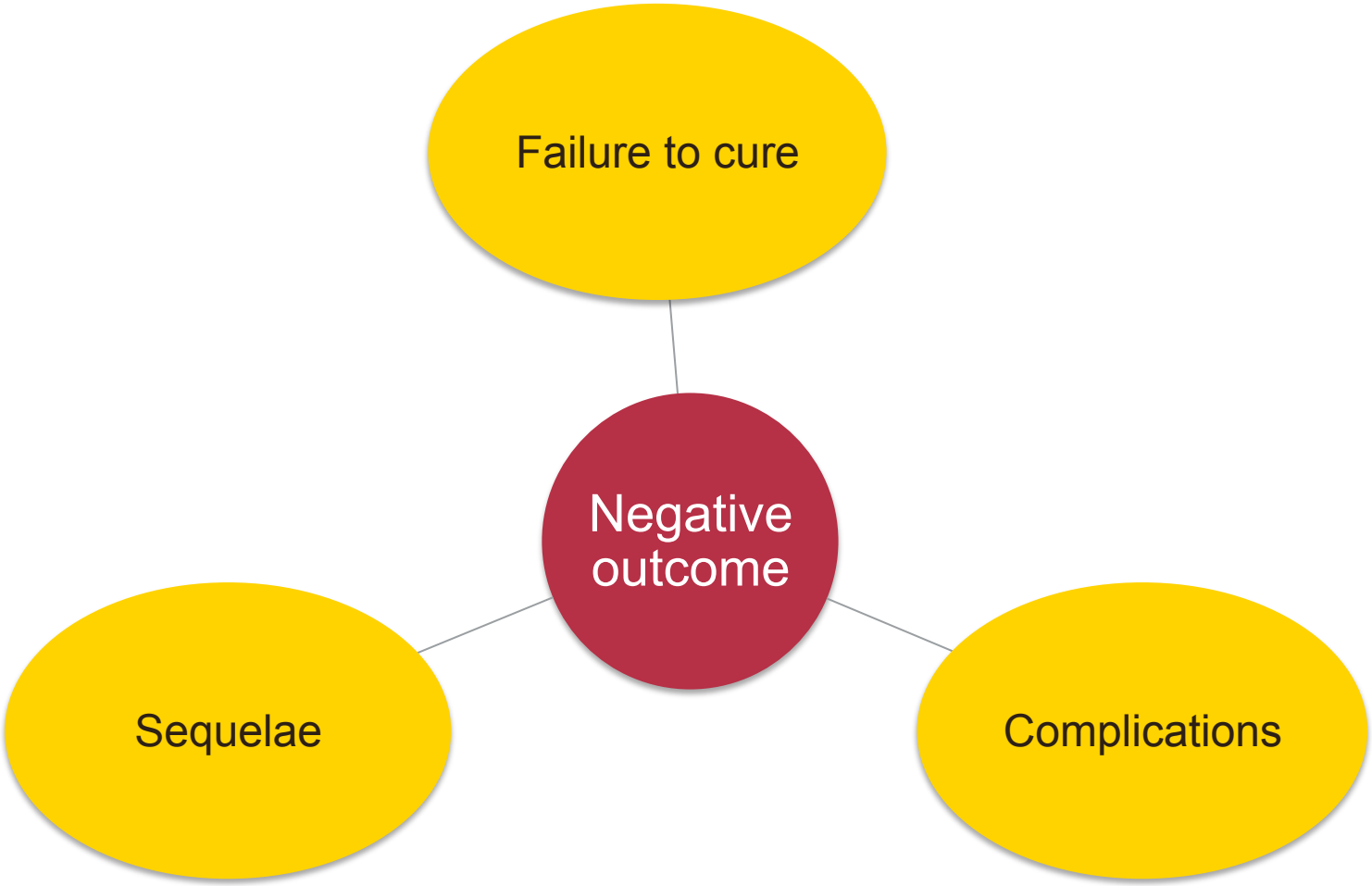
Failure to cure
Negative outcome
Sequelae
Complications

# Definition: Negative surgical outcomes

Complication: Any deviation from normal postoperative course (including asymptomatic events)
=> cardiac arrhythmia, hemorrhage,…

Sequela: “After-effect” of surgery inherent to the procedure
=> Walking impairment after limb amputation,…

Failure to cure: Purpose of surgery not achieved
=> tumor residual,…

# Dindo/Clavien Classification

- Based on therapy used to treat complication (retrospective documentation)
- Pro and retrospective analyses
- Not relying on subjective appraisals
- Independent from varying definitions
- Validation of reproducibility and acceptability

*Dindo, Ann Surg 2004; Clavien, Surgery 1992*

# Dindo/Clavien Classification

Complications Grade I

- Any deviation from normal postoperative course without the need for pharmacological treatment or surgical/endoscopic/radiological intervention

*Dindo, Ann Surg 2004; Clavien, Surgery 1992*

# Dindo/Clavien Classification

Complications Grade I

- Any deviation from normal postoperative course without the need for pharmacological treatment or surgical/endoscopic/radiological intervention
- Allowed: antiemetics, antipyretics, analgetics, diuretics, electrolytes, physiotherapy

*Dindo, Ann Surg 2004; Clavien, Surgery 1992*

# Dindo/Clavien Classification

Complications Grade I

- Any deviation from normal postoperative course without the need for pharmacological treatment or surgical/endoscopic/radiological intervention
- Allowed: antiemetics, antipyretics, analgetics, diuretics, electrolytes, physiotherapy

> Atelectasis requiring physiotherapy, transient serum creatinine elevation, wound infection treated on bedside

*Dindo, Ann Surg 2004; Clavien, Surgery 1992*

# Dindo/Clavien Classification

Complications Grade II

- Requiring pharmacological treatment other than allowed for grade I
- Includes blood transfusion, TPN

*Dindo, Ann Surg 2004; Clavien, Surgery 1992*

# Dindo/Clavien Classification

Complications Grade II

- Requiring pharmacological treatment other than allowed for grade I
- Includes blood transfusion, TPN

> Pneumonia treated with antibiotics, UTI requiring antibiotics, wound healing disorder with phlegmoneous infection

*Dindo, Ann Surg 2004; Clavien, Surgery 1992*

# Dindo/Clavien Classification

Complications Grade III

- Requiring surgical/endoscopic/radiological intervention

  IIIa: Not under general anesthesia

  IIIb: Under general anesthesia

*Dindo, Ann Surg 2004; Clavien, Surgery 1992*

# Dindo/Clavien Classification

Complications Grade III

- Requiring surgical/endoscopic/radiological intervention

  IIIa: Not under general anesthesia

  IIIb: Under general anesthesia

- IIIa: Bilioma after liver resection requiring percutaneous drainage, Pneumothorax requiring drainage
- IIIb: Ureteral stenosis requiring stenting, hemorrhage requiring re-operation, intestinal anastomotic leakage requiring relaparotomy

*Dindo, Ann Surg 2004; Clavien, Surgery 1992*

# Dindo/Clavien Classification

Complications Grade IV

- Life threatening complication including CNS requiring IC/ICU management

  IVa: Single organ dysfunction

  IVb: Multiorgan dysfunction

*Dindo, Ann Surg 2004; Clavien, Surgery 1992*

# Dindo/Clavien Classification

Complications Grade IV

- Life threatening complication including CNS requiring IC/ICU management

  IVa: Single organ dysfunction

  IVb: Multiorgan dysfunction

- ➢ IVa: Lung failure requiring intubation, renal insufficiency requiring dialysis
- ➢ IVb: lung failure combined with renal insufficiency, renal insufficiency combined with hemodynamic instability

*Dindo, Ann Surg 2004; Clavien, Surgery 1992*

# Dindo/Clavien Classification

Complications Grade V

- Death of patient

Suffix “d”

- Denotes disability after discharge => outcome, surveillance! (cardiomyopathy, hearing disorders,…)

*Dindo, Ann Surg 2004; Clavien, Surgery 1992*

# Dindo/Clavien Classification

Summary

- Simple, objective, and reproducible approach for comprehensive outcome assessment
- Applicable irrespective of individual variations
- Usable for all procedures/anatomical areas
- Evaluation and comparison of outcomes among different study populations (surgeons, centers, therapies)

# Complications in selected tumor entities

# Complication rates of pediatric tumor surgery

- Neuroblastoma: 8.7 – 34.8%
- Nephroblastoma: 8 – 25%
- Hepatoblastoma: 9 – 23%
- Sarcoma (RMS): 9.8 – 28.5%

*Rich 2011, Seitz 2010, Fuchs 2009, Günther 2009, Towu 2004, Stehr 2004, Schnater 2002, Godzinski 1996*

# Complications Neuroblastoma

- Gross total resection (GTR) ⇔ overall survival
- Tumor resectability ⇔ tumor relapse
- IDRF-based staging system ⇔ INSS
- Complications higher in GTR patients

*Rich 2011, J Pediatr Surg 2011; Monclair, J Clin Oncol 2009; Guenther, Eur J Pediatr Surg 2008*

# Intraoperative bleeding (midline neuroblastoma)

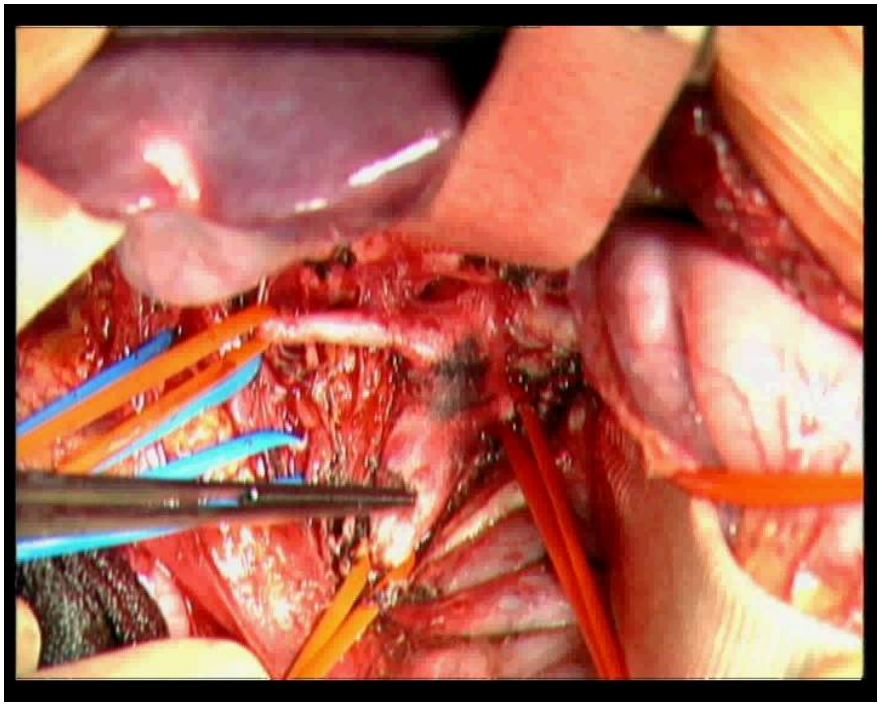

# Intraoperative bleeding (midline neuroblastoma)

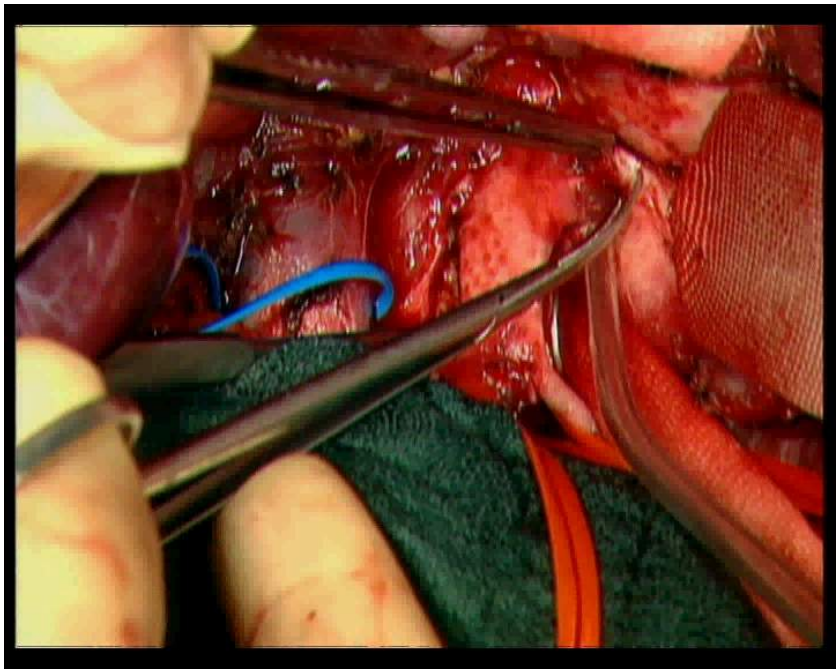

# Intraoperative bleeding (midline neuroblastoma)

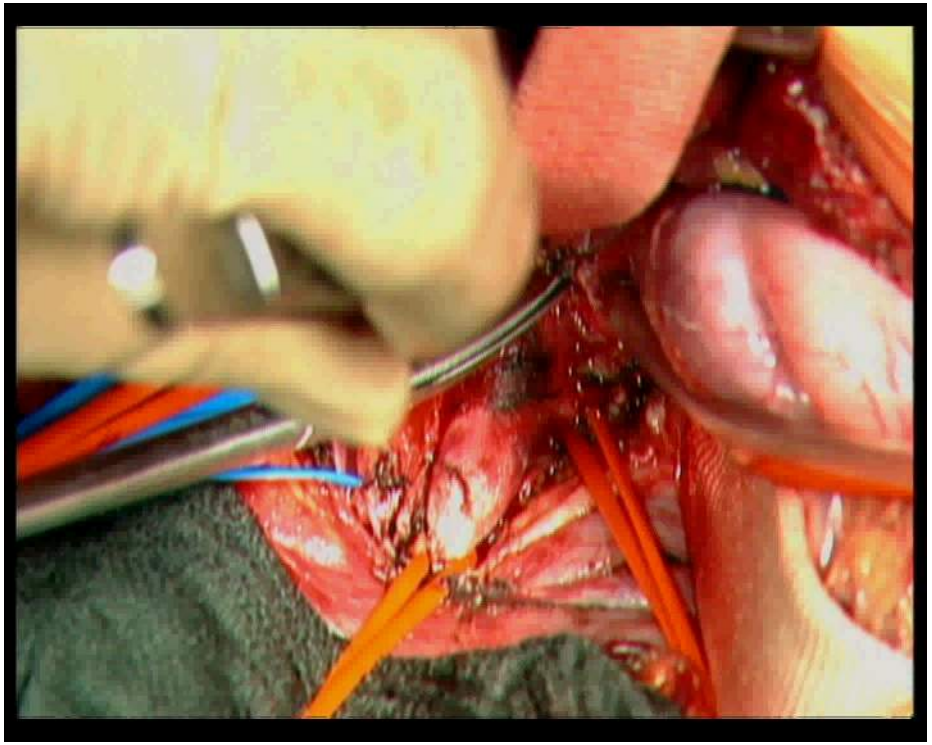

# Complications Stage IV Neuroblastoma

- Overall 35%
- 74% grade I, 3% grade IIIa, 22% Grade IIIb, 1% grade IVb
- GTR in 94% of patients despite IDRF
- Preservation of kidneys (nephrotoxic treatment)

*Rich 2011, J Pediatr Surg 2011; Guenther, Eur J Pediatr Surg 2008*

# Complications Stage IV Neuroblastoma

- Most common: Renal/polar atrophy, hydronephrosis, GI disorders
- Grade III/IV: GI, kidneys, vascular, abscess
- Morbidity comparable to overall NB results
- IDRF should not preclude GTR in high risk NB

*Rich 2011, J Pediatr Surg 2011; Guenther, Eur J Pediatr Surg 2008*

# Complications Nephroblastoma

- Preop chemotherapy

  => tumor shrinking, less ruptures, stage distribution
- Pretreated: 8-10%, primary operated: 20-25%
- Tumor rupture: up-staging, treatment intensification
- (Small bowel obstruction after chemotherapy)

*Fuchs, Ann Surg 2009; Stehr, Eur J Pediatr Surg 2005; Godzinski, Eur J Pediatr Surg 1998*

# Complications unilateral Nephroblastoma (SIOP 93-01/GPOH)

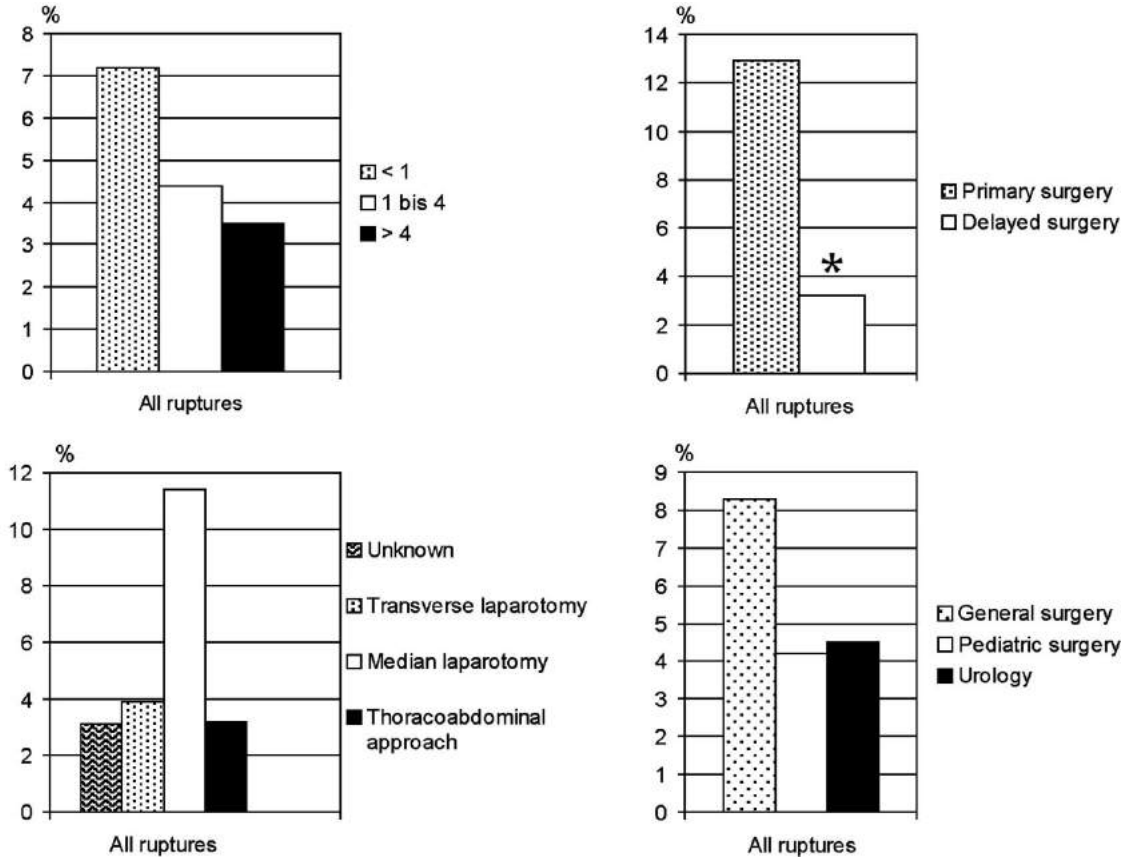


*Fuchs, Ann Surg 2009*

# Complications unilateral Nephroblastoma (SIOP 93-01/GPOH)

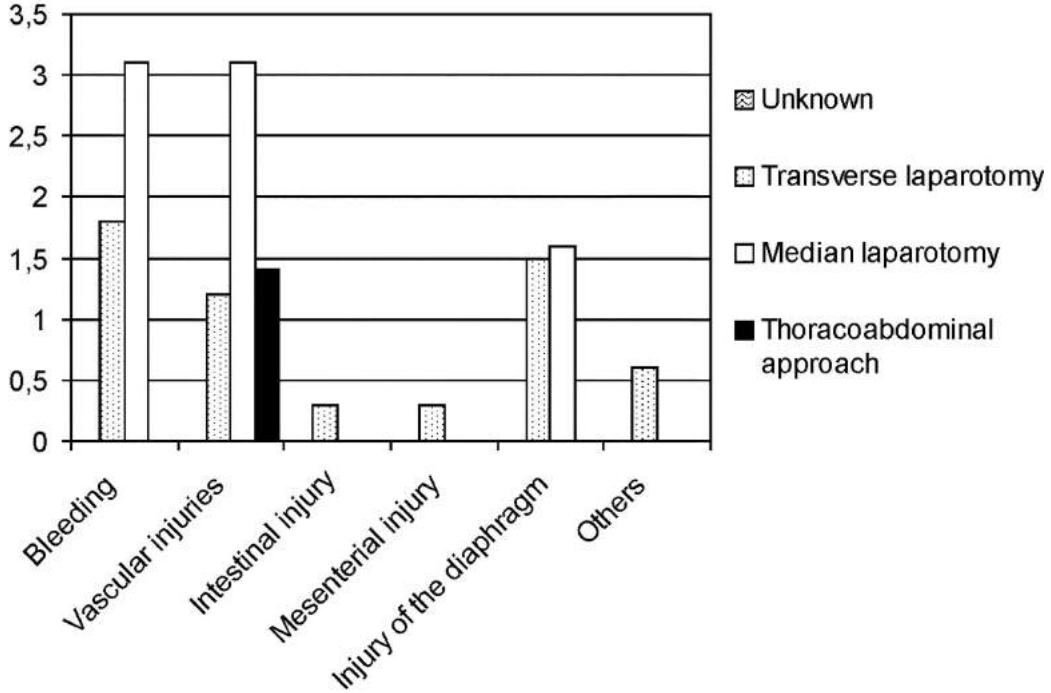


*Fuchs, Ann Surg 2009*

# Complications Hepatoblastoma

- Hemorrhage, biliary leakage, tumor rupture,…
- Intra-/ early postoperative mortality
- Tumor shrinkage through neoadjuvant chemotehrapy
- Postoperative complications! (pleural effusion, ascites, GI disorders, bile duct disorders,…)
- SIOPEL 1: morbidity 18%, intraop mortality 5%, biopsy complications 7%

*Towu, J Pediatr Surg 2004, Schnater, Cancer 2002*

# Biliary leakage (HB, mesohepatectomy)

- 4-year old boy, central HB, PR after chemo-Tx
- Mesohepatectomy, no intraoperative complications
- Postoperative bile leakage, conservative treatment unsuccessful

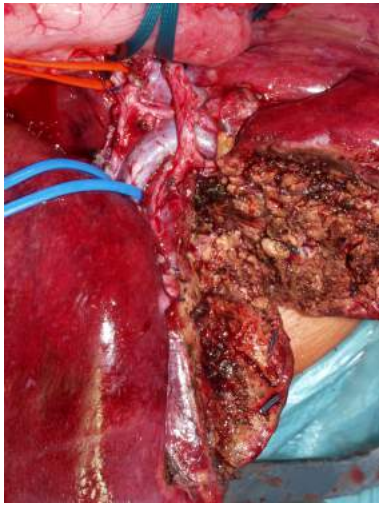

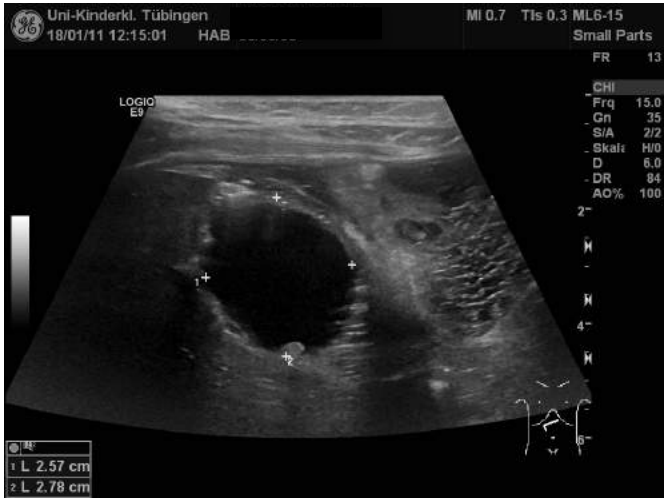

# Biliary leakage (HB, mesohepatectomy)

- 4-year old boy, central HB, PR after chemo-Tx
- Mesohepatectomy, no intraoperative complications
- Postoperative bile leakage, conservative treatment unsuccessful

# Biliary leakage (HB, mesohepatectomy)

- Further course: Bile leakage stopped after 8 days
- Stent removed after 6 weeks via endoscopy
- NED after 11 months follow up

## Complications Bladder/prostate-Rhabdomyosarcoma

- Secondary surgery: 29%

  => Bowel perforation, intestinal fistula, abscess, ileus, UTI, hemorrhage, ureteral stenosis, peritonitis, erectile dysfunction, neurogenic bladder,…
- Complication rates 2.5% higher without biopsy
- Late complications in up to 54% (but! radiation…)

*Seitz, Pediatr Blood Cancer 2011; Cechetto, Cancer 2007; Spunt, JCO 2005*

# Selected aspects of prevention

# Prevention of surgical complications

- Patient selection
- Diagnostic workup
- Operation planning
- Surgical strategy
- OR-preparation
- …

# Indication as element of complication prevention

- Example: 3.5-year old boy with multilocular stage IV hepatoblastoma
- Thrombus IVC, right HV
- PR after neoadjuvant chemotherapy, Lung mets cleared
- Extended resection ⇔ Primary transplantation

# Indication as element of complication prevention

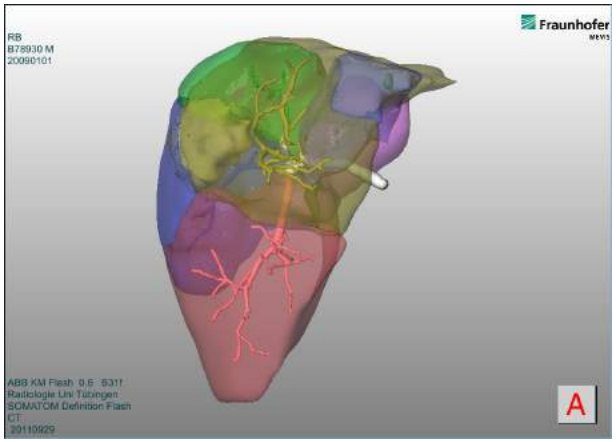


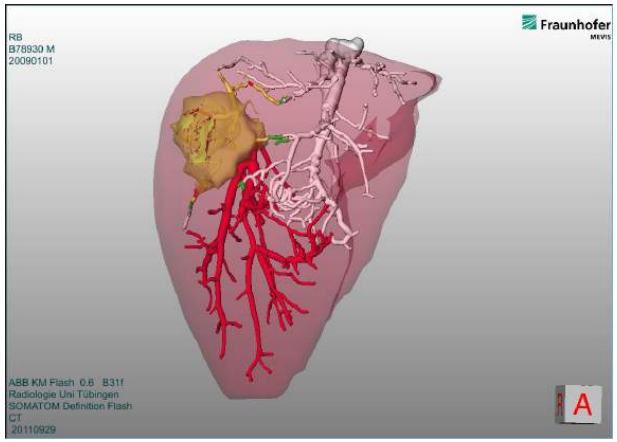


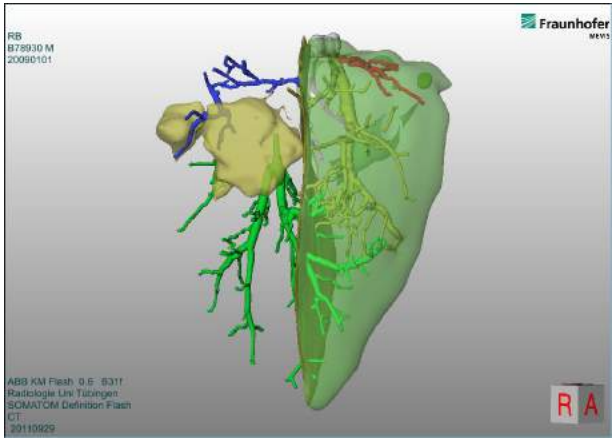


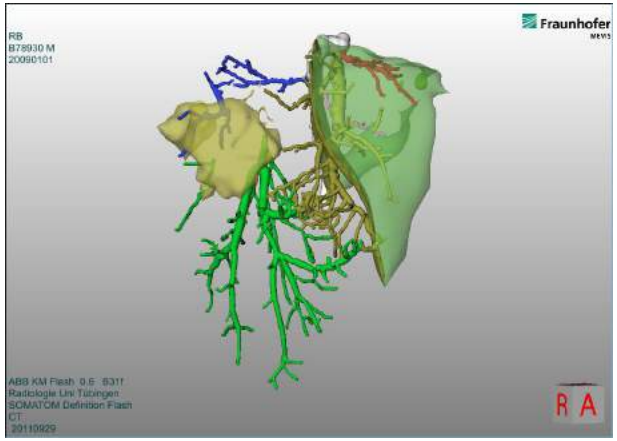

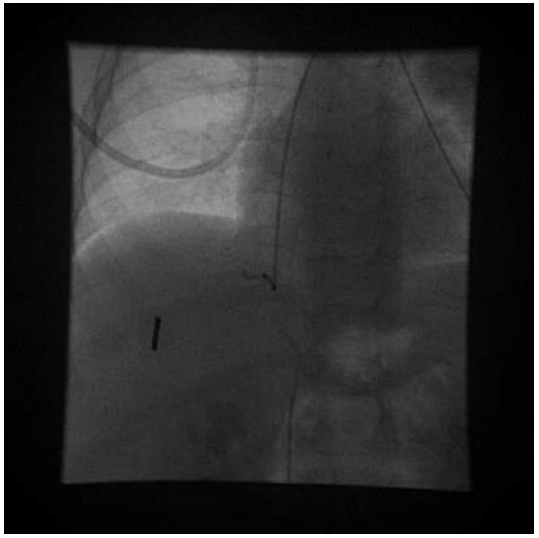

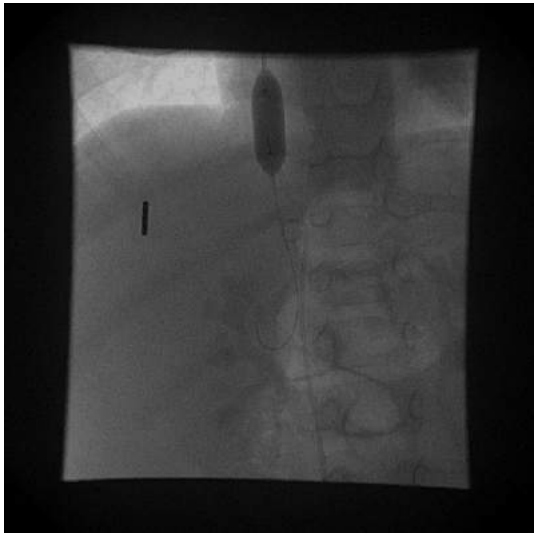

# Indication as element of complication prevention

Procedure:

- LRLTx (Seg. II, III)
- No surgical complications
- ICU 5 days, hospital stay 21 days

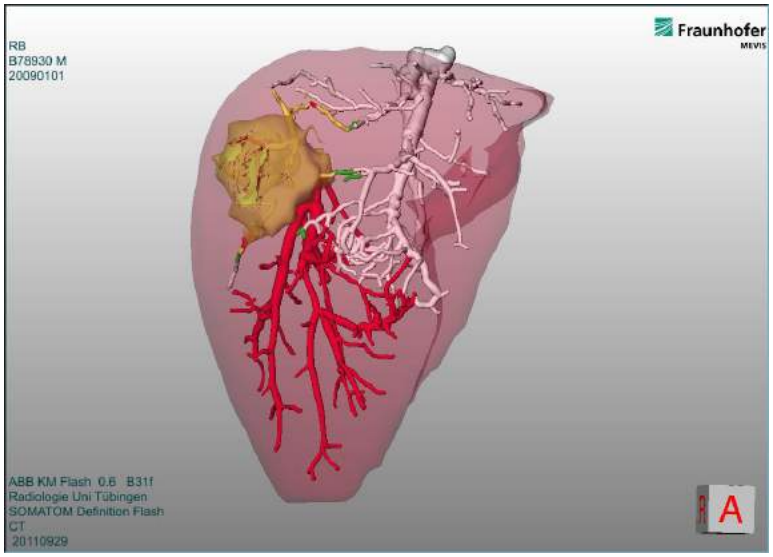

# Reduction of surgical treatment intensity

Pre-/ intraoperative labeling of lung metastases

# Preop/intraop CT-guided labeling

# Preop/intraop CT-guided labeling

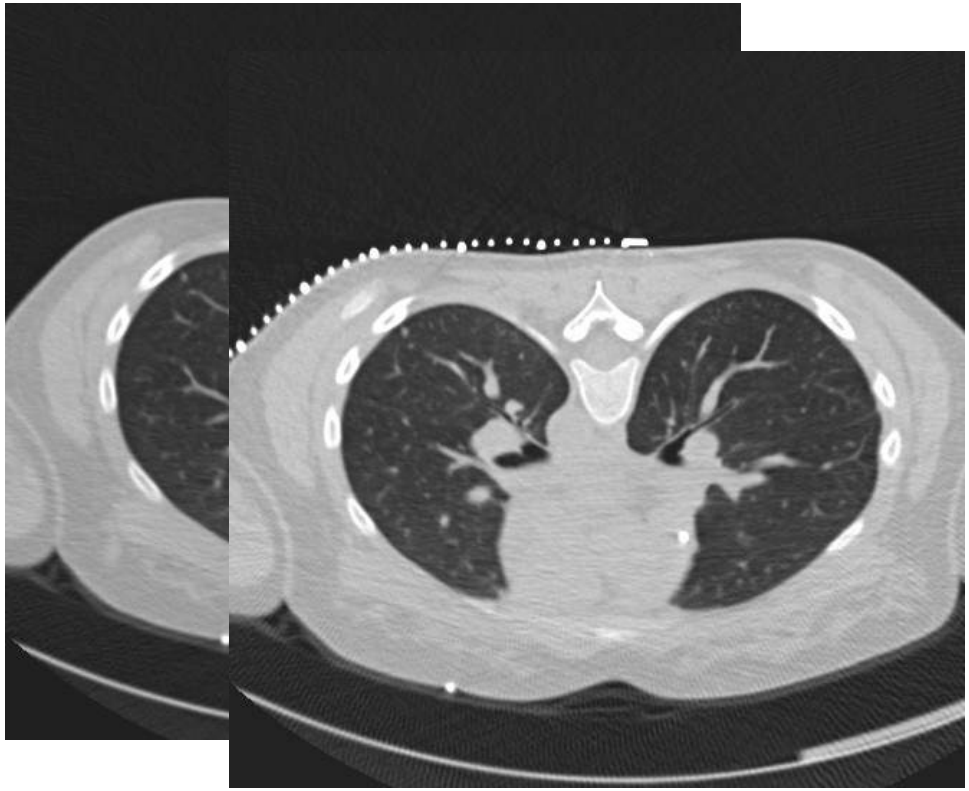

# Preop/intraop CT-guided labeling

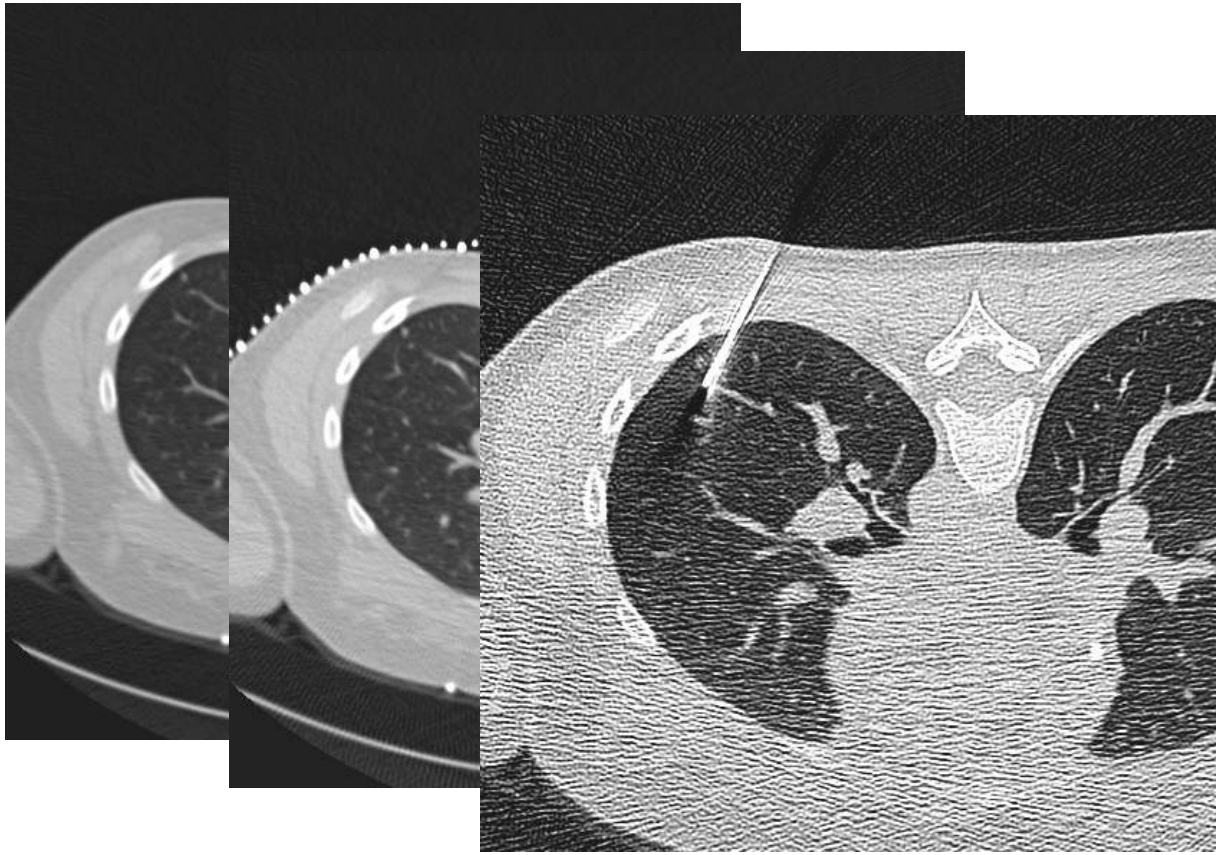

# Preop/intraop CT-guided labeling

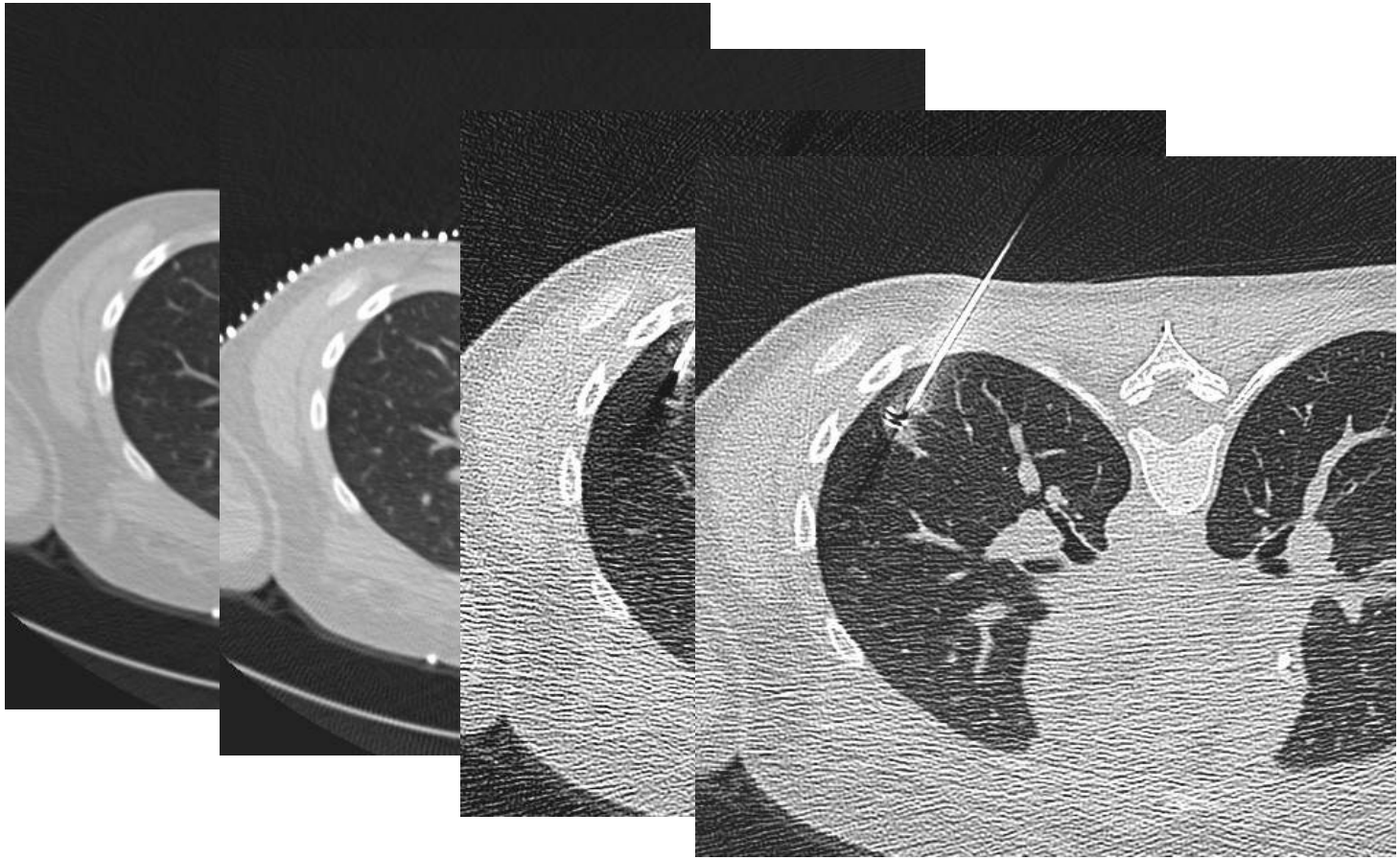

# Preop/intraop CT-guided labeling

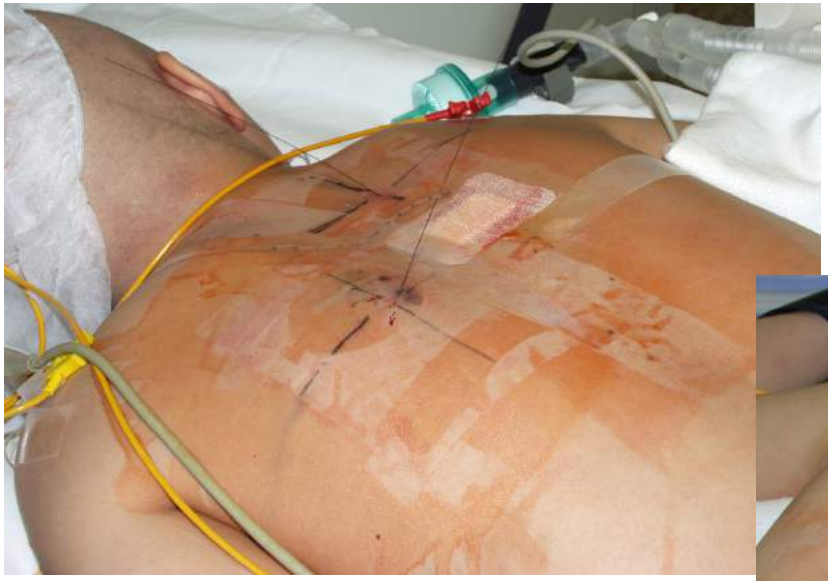

# Preop/intraop CT-guided labeling

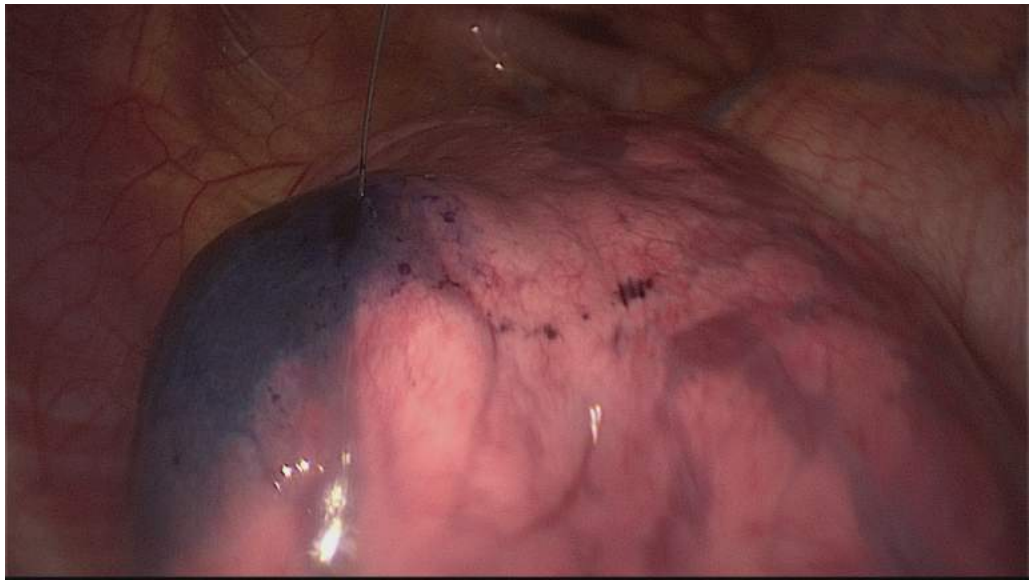

# Preop/intraop CT-guided labeling

# Preop/intraop CT-guided labeling

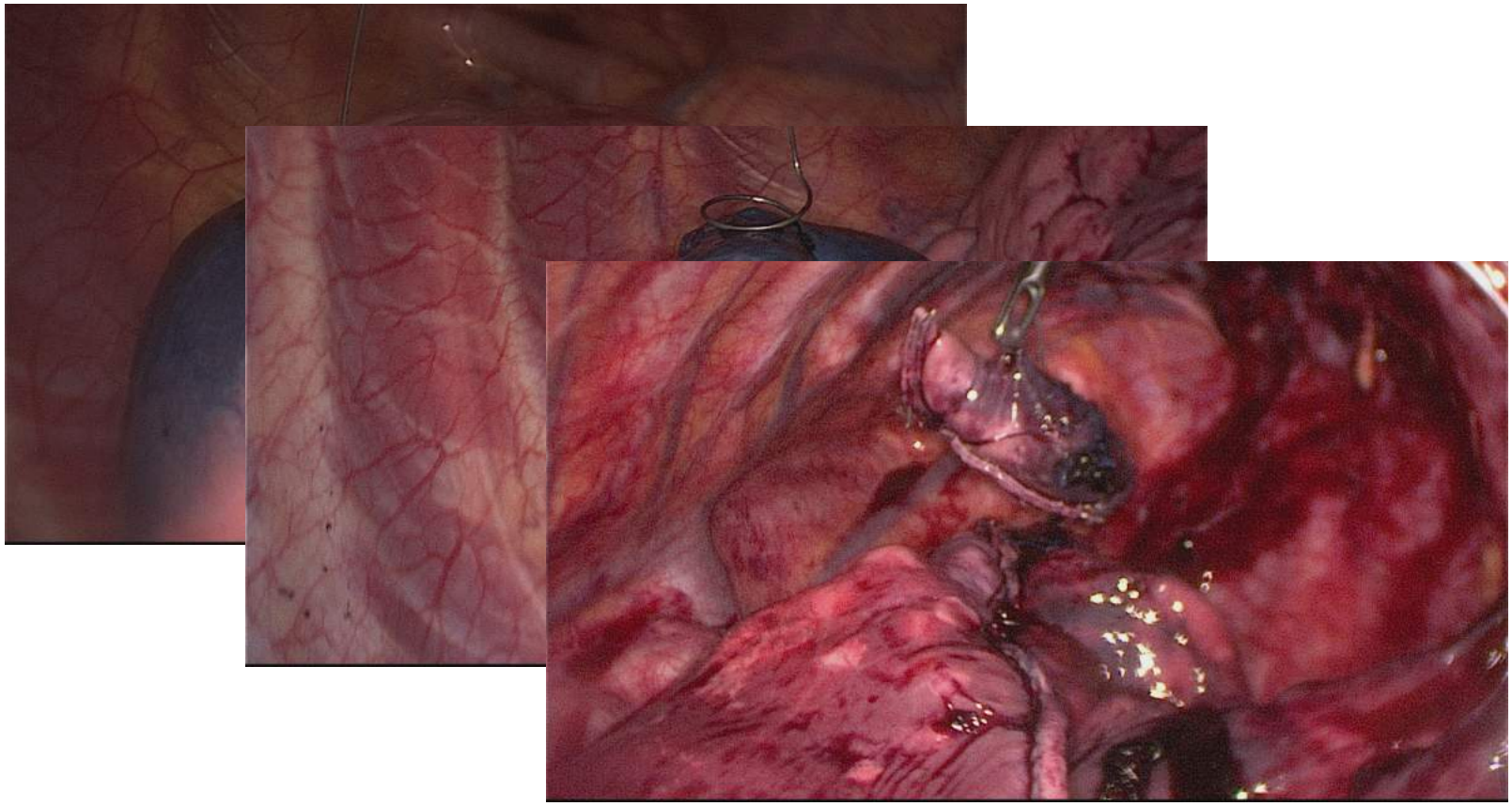

# Management of selected surgical complications

# Vascular stenosis (midline neuroblastoma)

- 3-year old boy, midline NB stage III
- Chemotherapy + irradiation (dose?)
- Intraoperative subtotal laceration of left renal artery
- Autotransplantation of left kidney
- Postoperative stenosis of both art. ren.

  => Interventional treatment

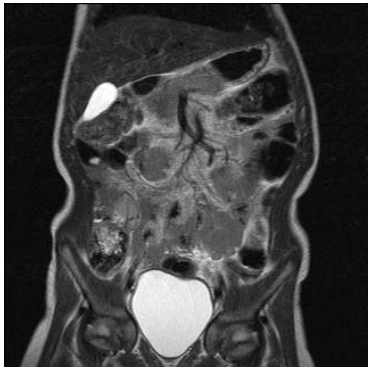
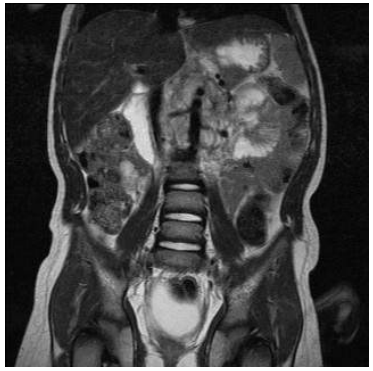
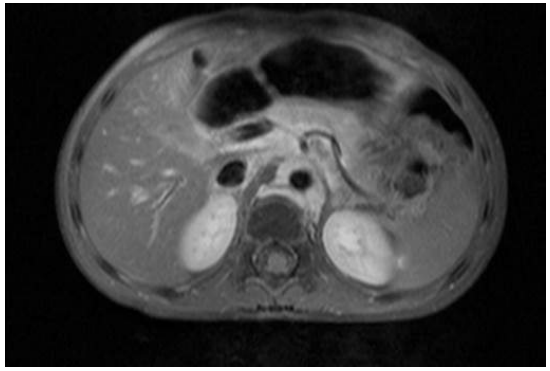

# Vascular stenosis (midline neuroblastoma)

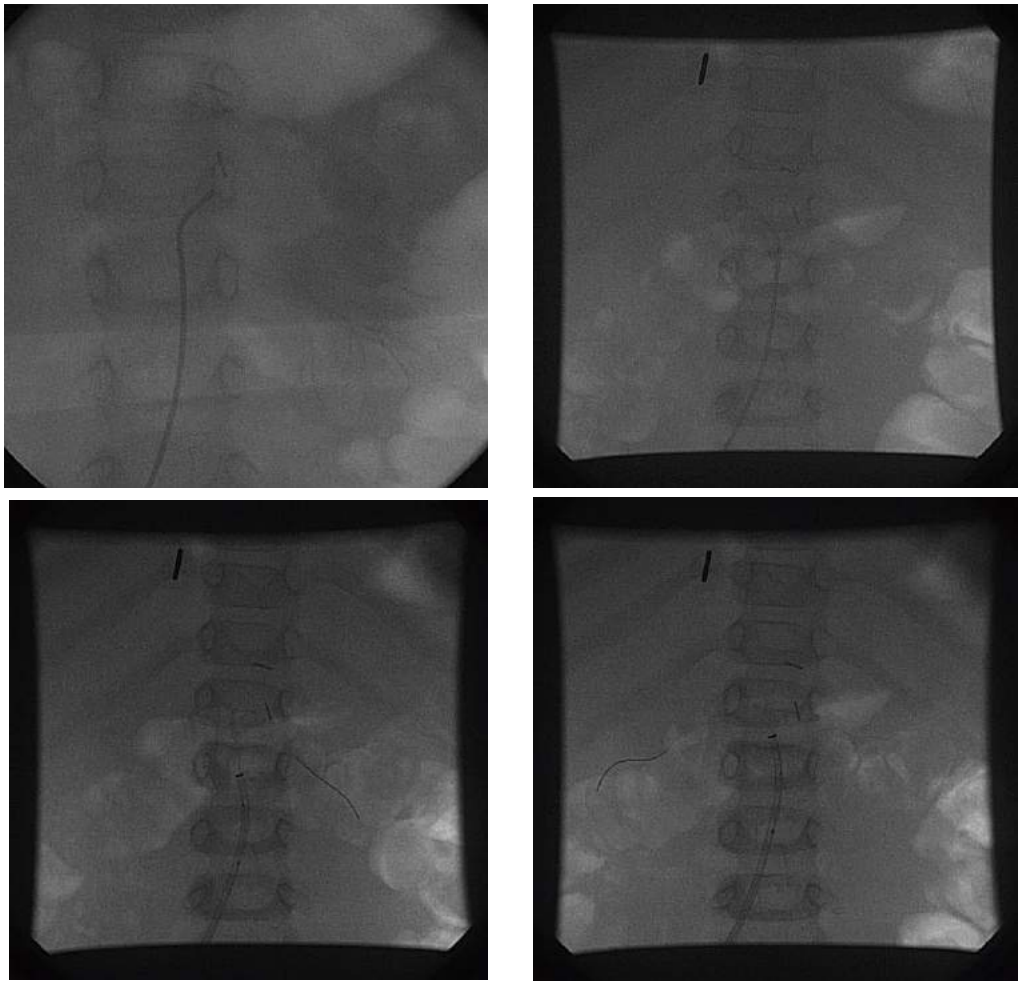

# Vascular stenosis (midline neuroblastoma)

- 3-year old boy, midline NB stage III
- Chemotherapy + irradiation (dose?)
- Intraoperative subtotal laceration of left renal artery
- Autotransplantation of left kidney
- Postoperative stenosis of both art. ren. => Intervention

Postoperative course:

- Increasing failure right kidney, nephrectomy (r) after 10 months
- Outcome: NED, normal renal function (5y1m)

# Nerve reconstruction/replacement

- 11-year old girl, Desmoid-tumor relapse proximal Ulna with infiltration of ulnar nerve
- Preoperative significant loss of ulnar nerve function
- En-bloc resection of tumor and nerve with interposition using sural nerve

# Nerve reconstruction/replacement

- 11-year old girl, Desmoid-tumor relapse proximal Ulna with infiltration of ulnar nerve

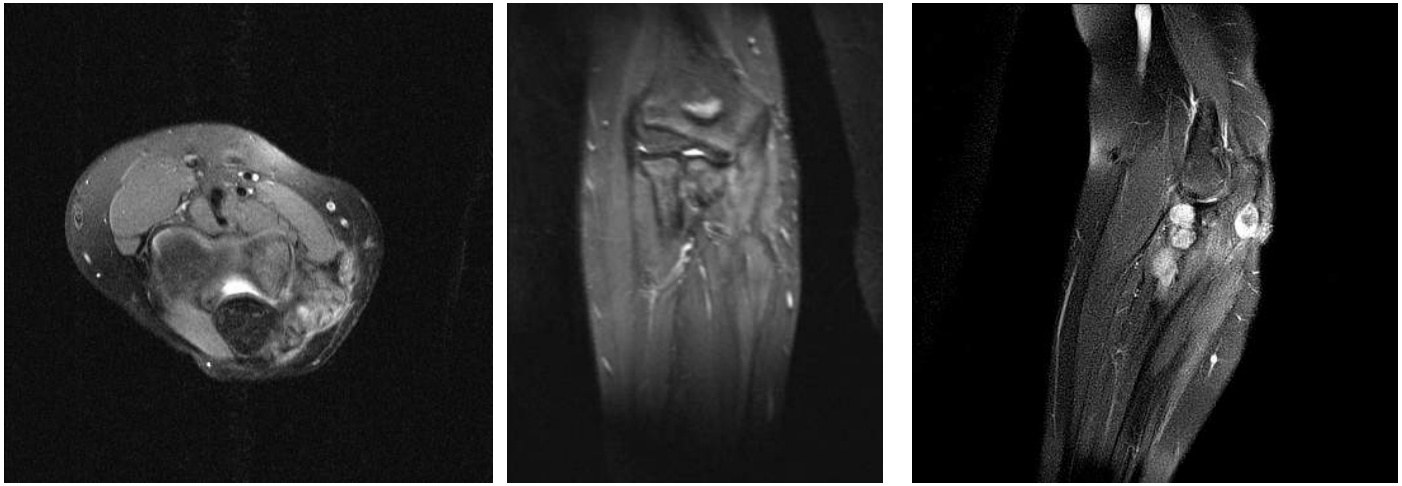

# Nerve reconstruction/replacement

- En-bloc resection of tumor and nerve with interposition using sural nerve

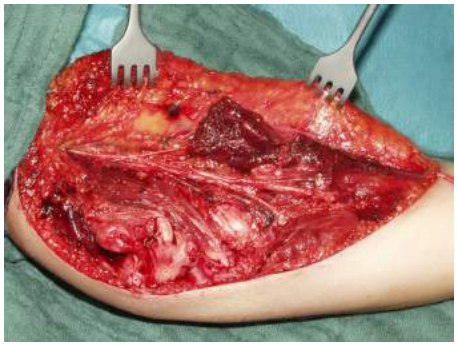

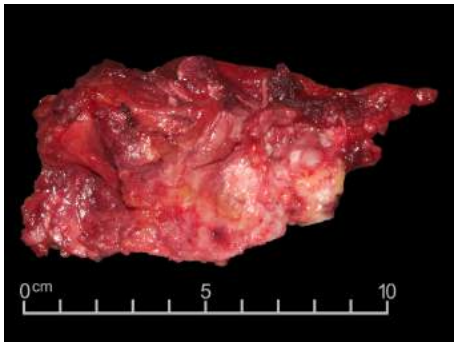

# Nerve reconstruction/replacement

- Outcome: Near-total restoration of nerval function, NED after 3.5 years follow-up

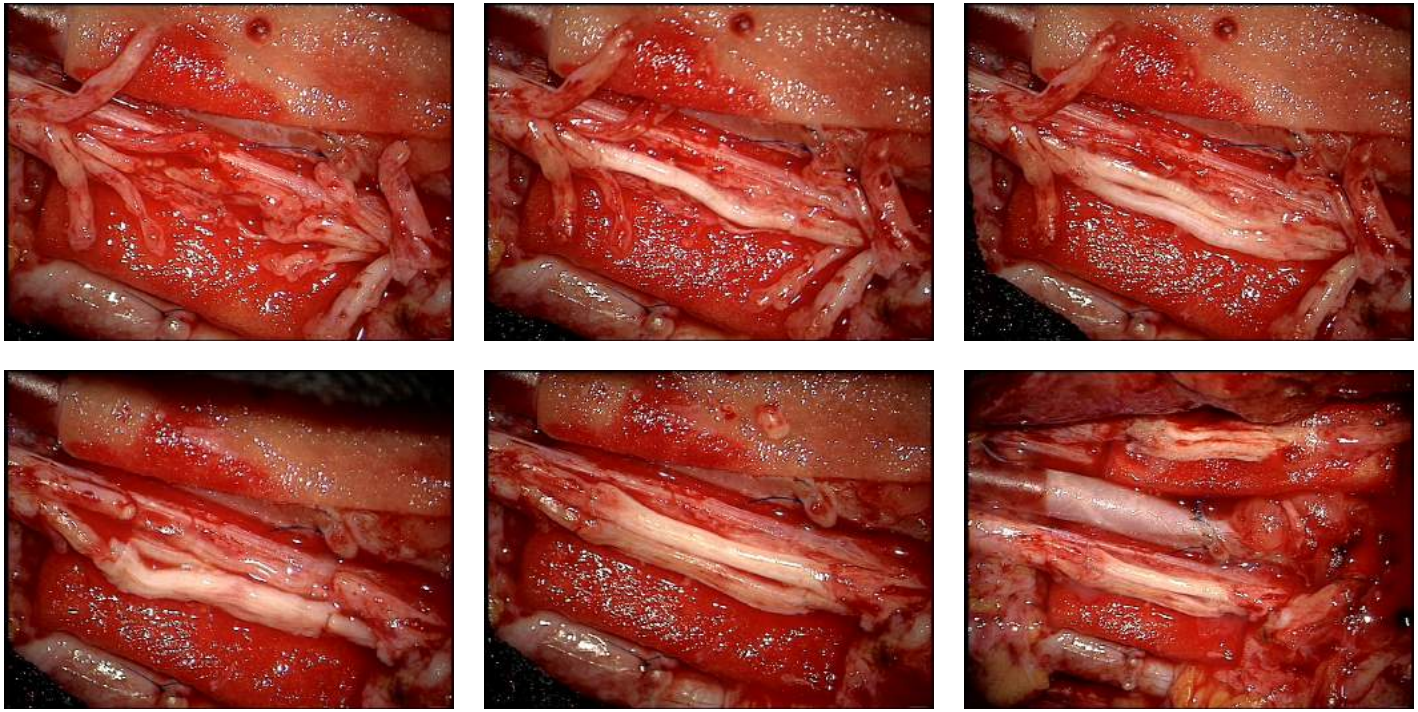

# Summary



- Advanced pediatric surgical oncology is regularly associated with a relevant surgical morbidity.
- Classification of complications should be performed in any analysis of surgical procedures.
- A complete prevention of surgical events is unrealistic. However, the extension of surgical complications can be limited through distinct measures.
- The consequent, target-oriented, and rapid management of surgical complications is essential for achieving the best possible outcome.
- As for pediatric oncology in general, the treatment of surgical complications requires an interdisciplinary approach.

Only to those that do nothing,

nothing will happen…

EBERHARD KARLS UNIVERSITÄT TÜBINGEN

UKT Eberhard-Karls-Universität Universitätsklinikum Tübingen

UKT Eberhard-Karls-Universität Universitätsklinikum Tübingen

4th International Tübingen-Symposium on Pediatric Solid Tumors

From Bench to Bedside in Neuroblastoma

February 16-18th, 2012 · Tübingen, Germany

From Bench to Bedside in Neuroblastoma

www.neuroblastoma2012.com

4th World Conress of Pediatric Surgery (WOFAPS)

October 2013, Berlin, Germany

www.wofaps.org

EBERHARD KARLS UNIVERSITÄT TÜBINGEN

UKT Eberhard-Karls-Universität Universitätsklinikum Tübingen

UKT Eberhard-Karls-Universität Universitätsklinikum Tübingen

4th International Tübingen-Symposium on Pediatric Solid Tumors

From Bench to Bedside in Neuroblastoma

February 16-18th, 2012 · Tübingen, Germany

From Bench to Bedside in Neuroblastoma

www.neuroblastoma2012.com

4th World Conress of Pediatric Surgery (WOFAPS)

October 2013, Berlin, Germany

www.wofaps.org

EBERHARD KARLS UNIVERSITÄT TÜBINGEN

UKT Universitätsklinikum Tübingen

## 4th International Tübingen-Symposium on Pediatric Solid Tumors

From Bench to Bedside in Neuroblastoma

February 16-18th, 2012 · Tübingen, Germany

www.neuroblastoma2012.com

# Survival stage IV Neuroblastoma

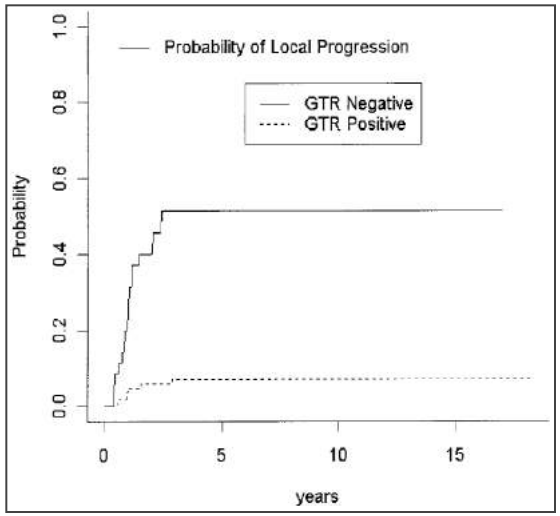


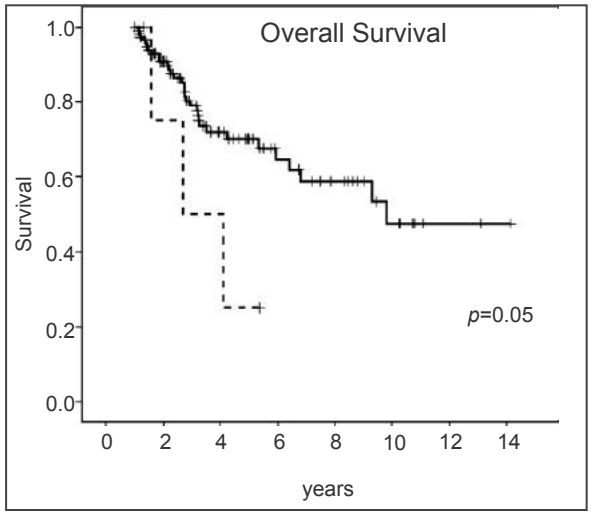


- Local control and overall survival correlate with GTR in high risk-NB
- Encasement of major vessels does not preclude GTR

*Rich 2011, J Pediatr Surg 2011; La Quaglia, J Pediatr Surg 2004*

# Preop/intraop CT-guided labeling

- No. of patients n = 6
- Preop/intraop n = 4/2
- Age at surgery 8.5y (4.3-15.5)* (*median, range)
- $R_0$ after surgery n = 6
- Complications ./.

# Pyelon resection and reconstruction in central BWT

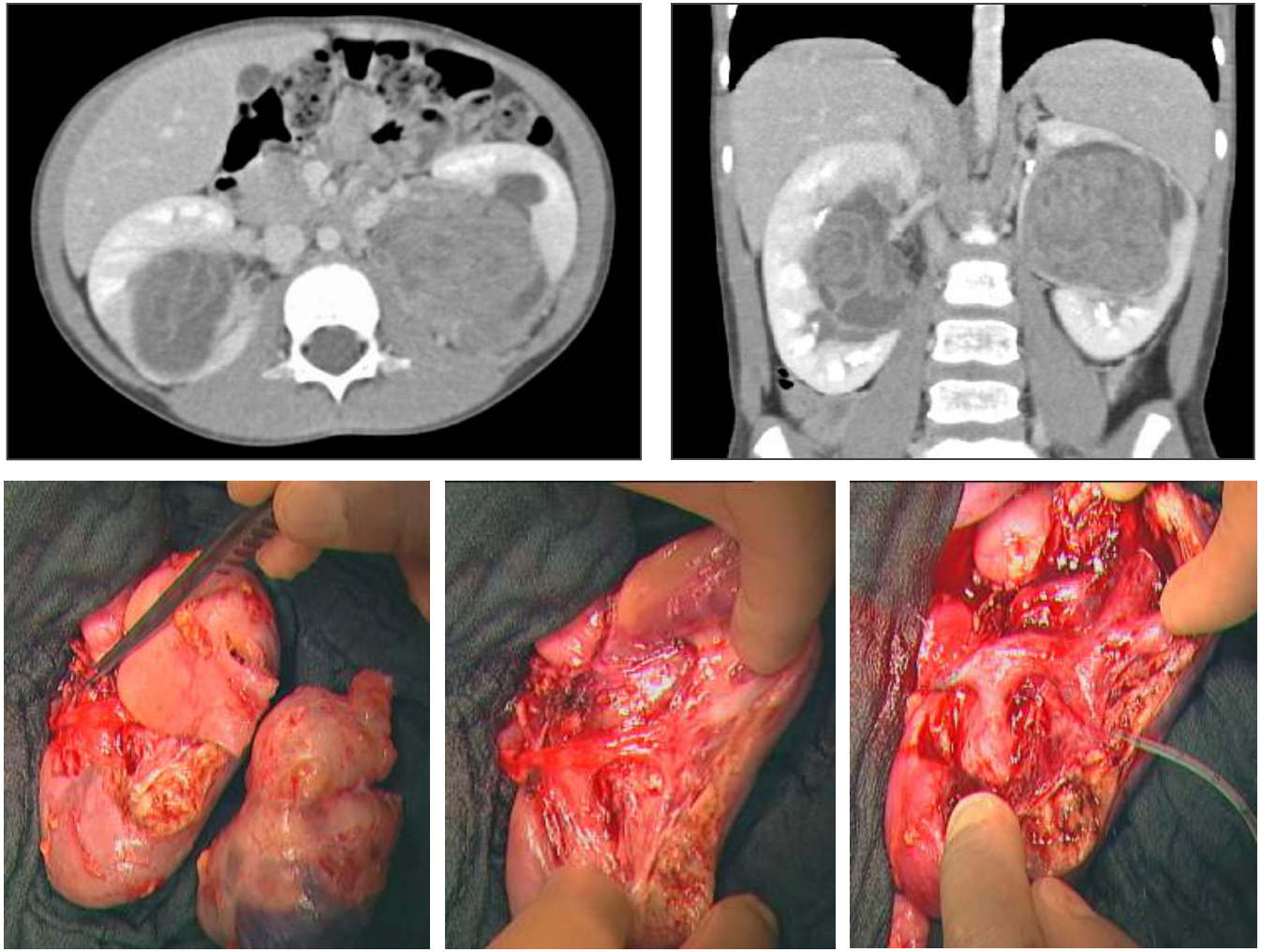

*Fuchs, J Urol 2011*

# Management of renal remnant

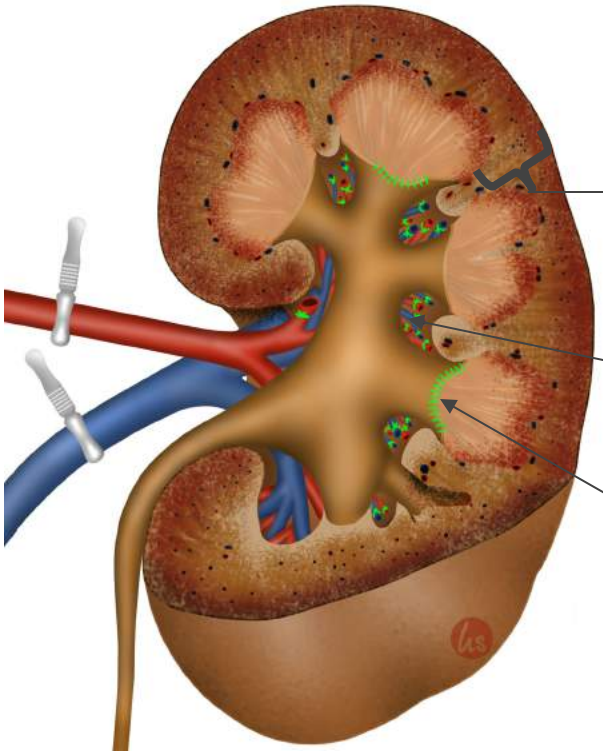

Area of bipolar coagulation

Area of selective vascular suturing

Reconstruction of renal pelvis

*Fuchs, J Urol 2011*

# LPN in a 2.9 year-old boy

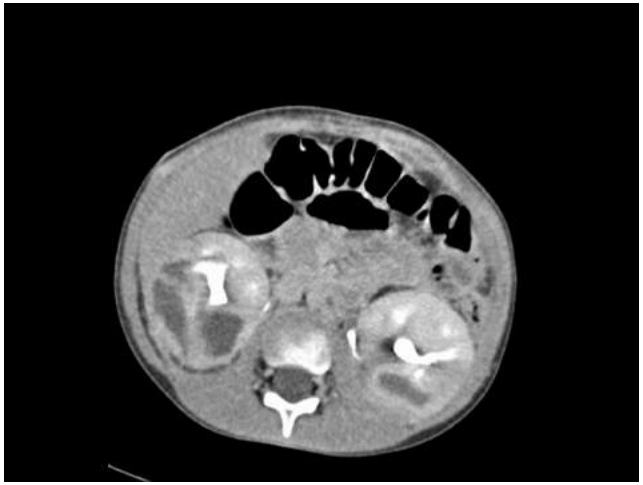

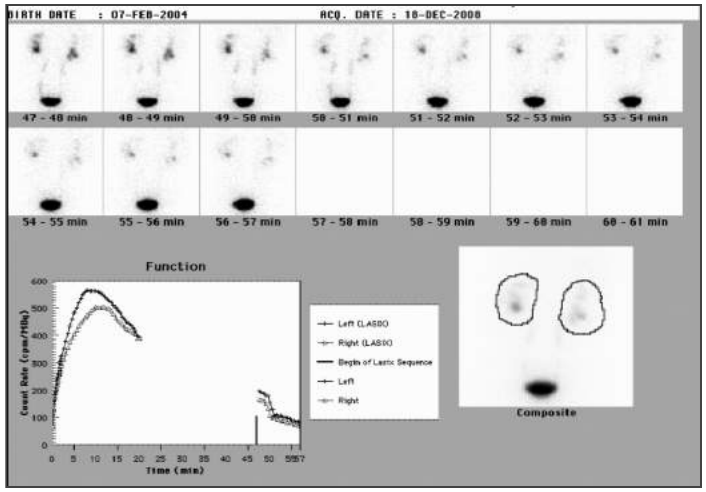


*Fuchs, J Urol 2011*

# Results - complications

- Urinary leakage n = 2/6
  - *Re-operation* *n = 1*
  - *CT-guided drainage* *n = 1*

- Blood transfusion 11.9 (0-33.3) ml/kg
- FFP 21.9 (9.3-38.9) ml/kg

*Fuchs, J Urol 2011*