Malignant Salivary Gland Tumors in Children

Dr. Sajid. S. Qureshi

Associate Professor, Pediatric Oncology
Tata Memorial Hospital
Mumbai, INDIA

- Tumors of salivary gland are relatively uncommon in children and adolescents - 1% of all pediatric neoplasms
- 8% of all pediatric head and neck neoplasms
- 35% of all salivary gland masses in children are malignant

- Rarity of salivary gland tumors makes it impossible for any institution to gain solid experience in their diagnosis and therapy.

- Salivary gland tumors treated between January 2005- June 2011
- Benign tumors were excluded

Demography

- 21 patients with malignant salivary gland tumor
- Median age – 10.5 years (range 5 – 17 years)
- Male : Female – 13:8

Symptoms

- Median duration of symptoms – 6 months (range 15 days – 3 years)
- Commonest symptom – swelling
- Pain occasional
- Facial nerve palsy – 1 (post surgery)

Previous surgery: 7 patients

Metastatic disease : 6 patients

Anatomical location

- Parotid: 16 patients
- Submandibular gland: 3 patients
- Minor salivary gland: 2 patients


TATA MEMORIAL CENTRE
टाटा स्मारक केंद्र
SERVICE
RESEARCH
EDUCATION

Surgery

- Superficial parotidectomy: 3
- Total nerve sparing parotidectomy: 9
- Total parotidectomy: 4
- Submandibular gland excision: 3
- Wide excision: 2

Superficial parotidectomy

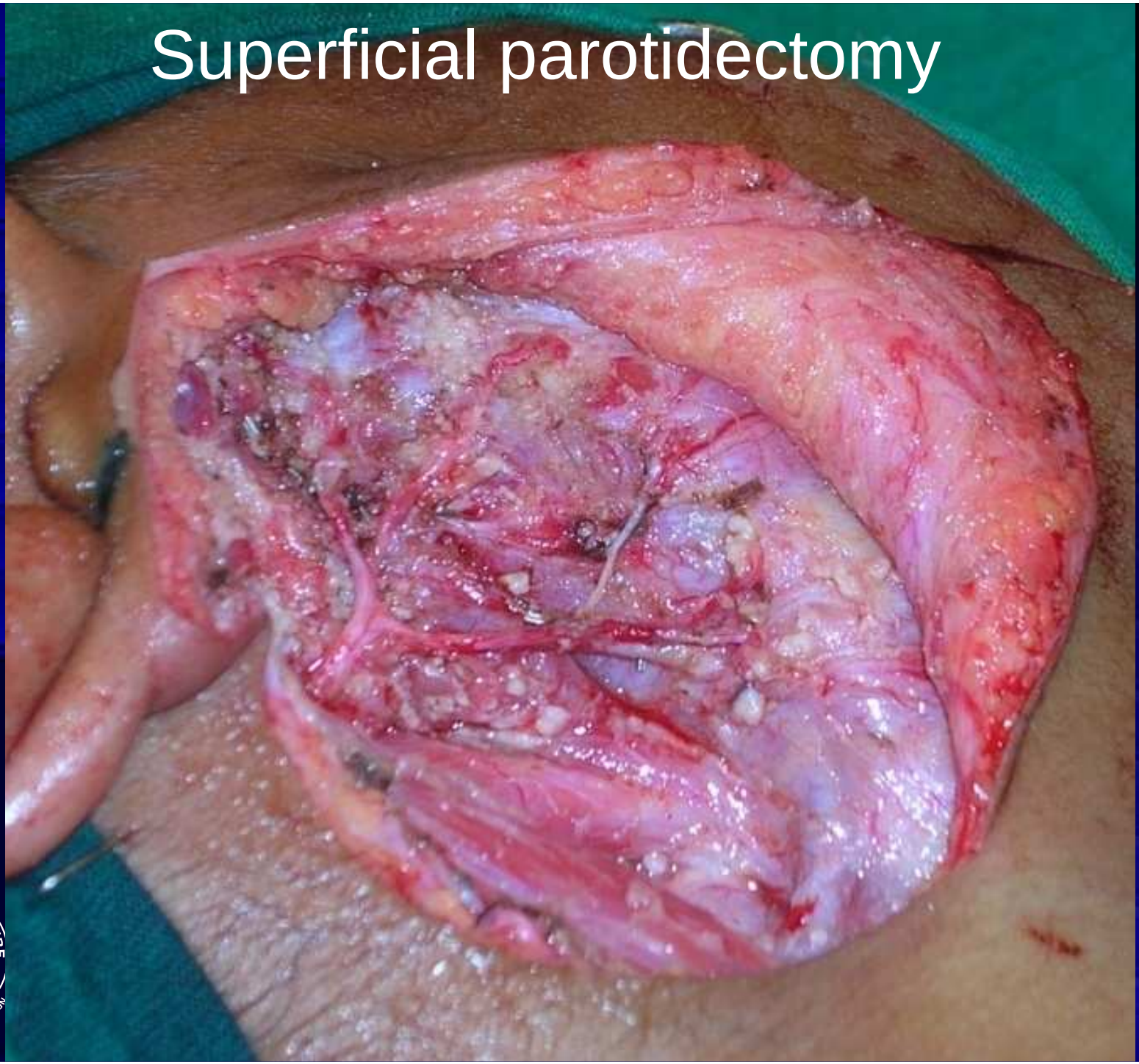

Nerve Sparing Total Parotidectomy

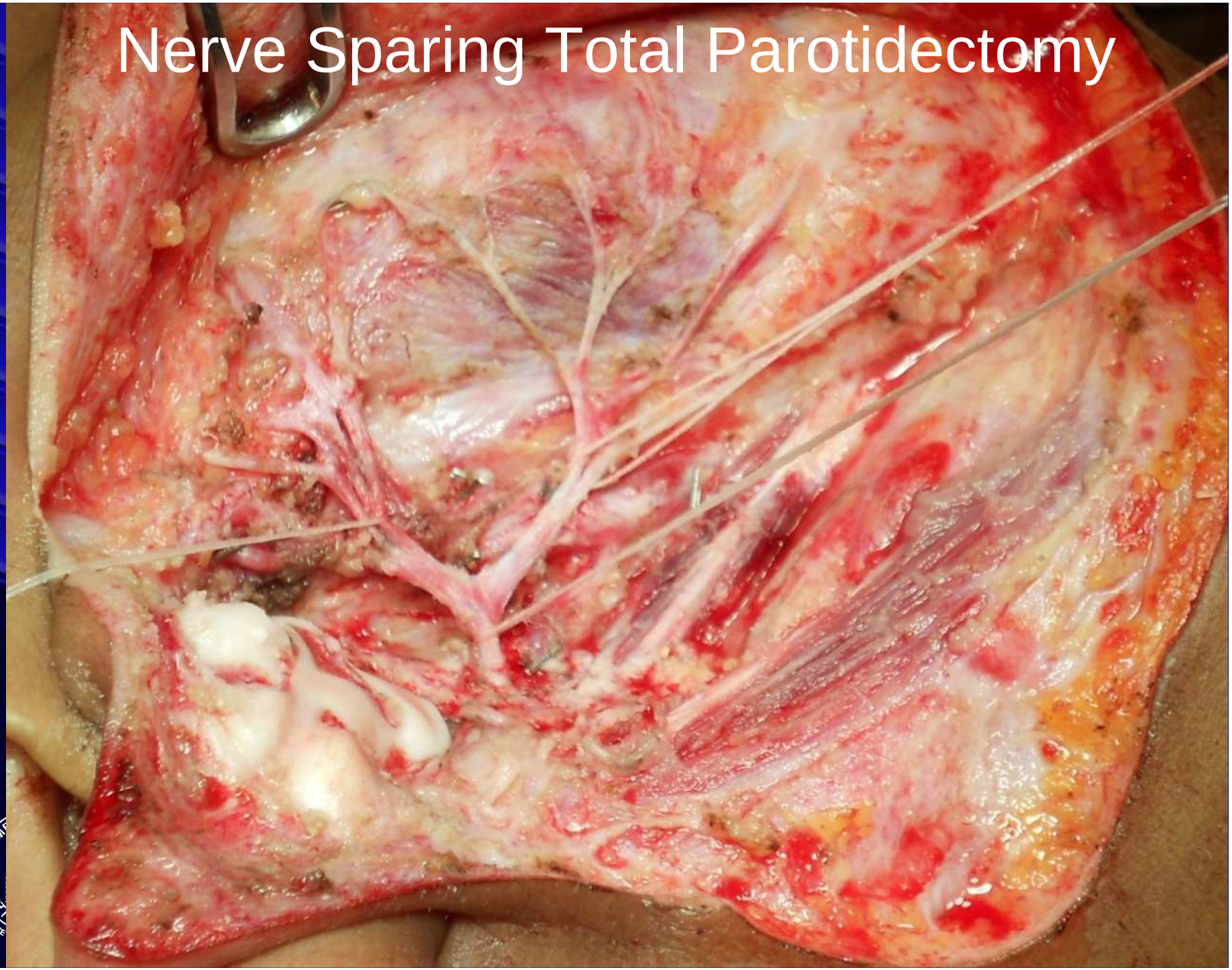

Total Parotidectomy

Surgery

- Node dissection/sampling: 19
- Node positive: 7
- Reconstruction:
  - Free ALT flap: 2
  - PMMC flap: 2
  - Local flap: 2
  - SSG: 1

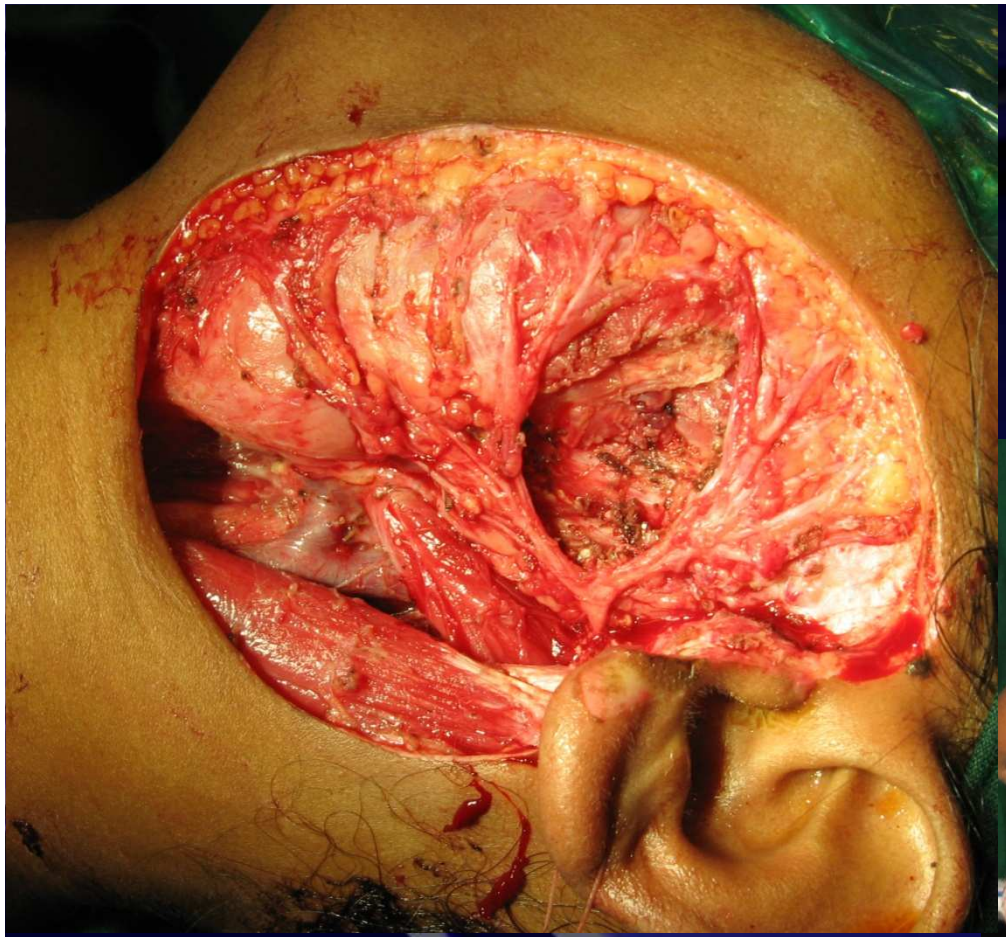

Free Flap

TATA MEMORIAL CENTRE
टाटा स्मारक केंद्र
SERVICE RESEARCH EDUCATION

Local Island Flap

PMMC Flap

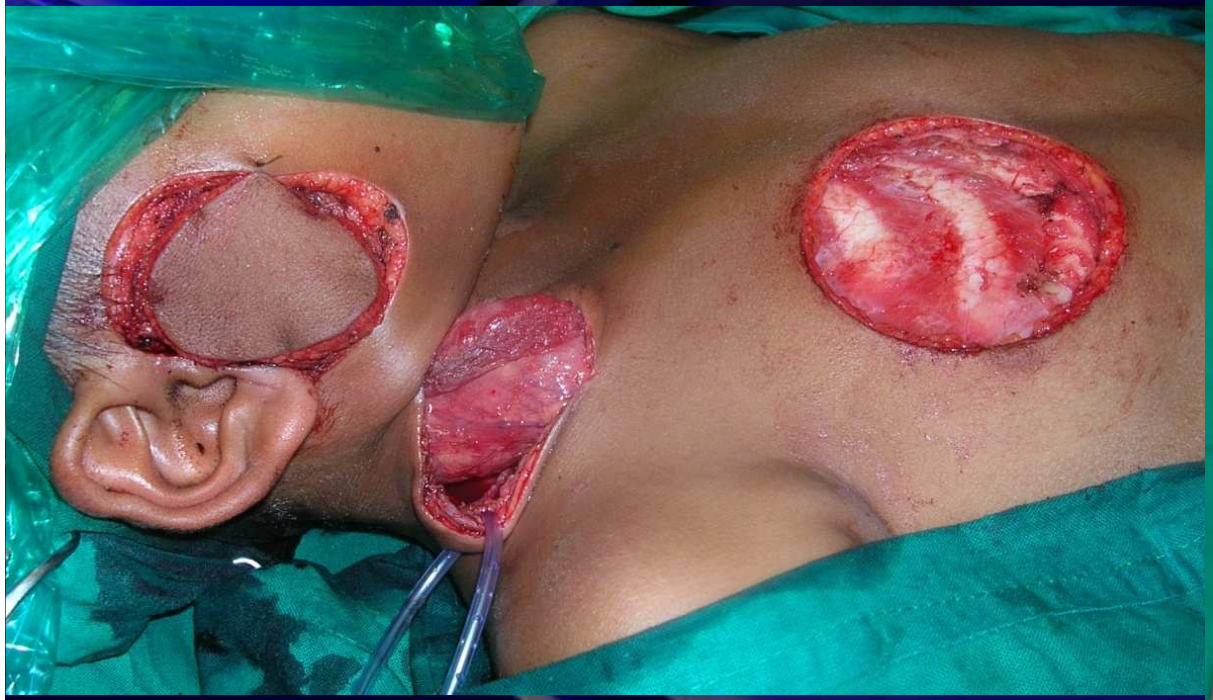

Histopathology

- Mucoepidermoid carcinoma: 13
  - Low grade: 8
  - Intermediate grade: 4
  - High: 1
- Acinic cell carcinoma: 1
- Rhabdomyosarcoma: 1
- Metastatic: 6
  - Medulloepithelioma: 2
  - Undifferentiated nasopharyngeal carcinoma: 2
  - Squamous cell carcinoma (XP): 2

Adjuvant therapy

- Radiotherapy: 11
  - Mucoepidermoid carcinoma: 5
    - Low grade: 3
    - Intermediate grade: 1
    - High: 1
  - Acinic cell carcinoma: 1
  - Rhabdomyosarcoma: 1
  - Metastatic: 4
    - Medulloepithelioma: 2
    - Undifferentiated nasopharyngeal carcinoma: 2

Recurrence

- Mucoepidermoid carcinoma: Nil
- Acinic cell carcinoma: Nil
- Rhabdomyosarcoma: Nil
- Metastatic: 4
  - Medulloepithelioma: 1 (Total parotidectomy with PMMC)
  - Undifferentiated nasopharyngeal carcinoma: 1 (Axillary LN, followed by neck relapse – died of disease after 5 years)
  - Squamous cell carcinoma (XP): 2
    - New lesions cutaneous and mucosal- both lost to follow-up

Survival

- Median Follow-up – 24 months
- All patients with primary malignant salivary gland tumors are alive
- 2 patients with secondary tumors are alive and disease free
- 4 patients had disease relapse at other sites -2 died of disease and 2 are lost to follow-up

Conclusion

- Surgical excision is the mainstay of treatment of malignant salivary gland tumors in children.
- Metastatic disease is also effectively treated with surgical excision and radiotherapy.


Thank you