ENDOSURGERY IN PEDIATRIC ONCOLOGY

Institute of Pediatric Oncology and Hematology N.N. Blokhin Cancer Research center, Moscow

What do you need to develop endosurgery in pediatric oncology?

- Large experience in conventional surgery
- Standardization of surgery in multimodal treatment approach
- Large endosurgery experience in adults

Peculiarities of endosurgery in children

- ✓ small volume of abdominal and pleural cavities
- ✓ small size of all anatomical structures
- ✓ prolonged pneumoperitoneum
- ✓ impossible to separately intubate bronchi when performing thoracoscopic operations in children under 6 years old

Endoscopic operations per year (n=309)

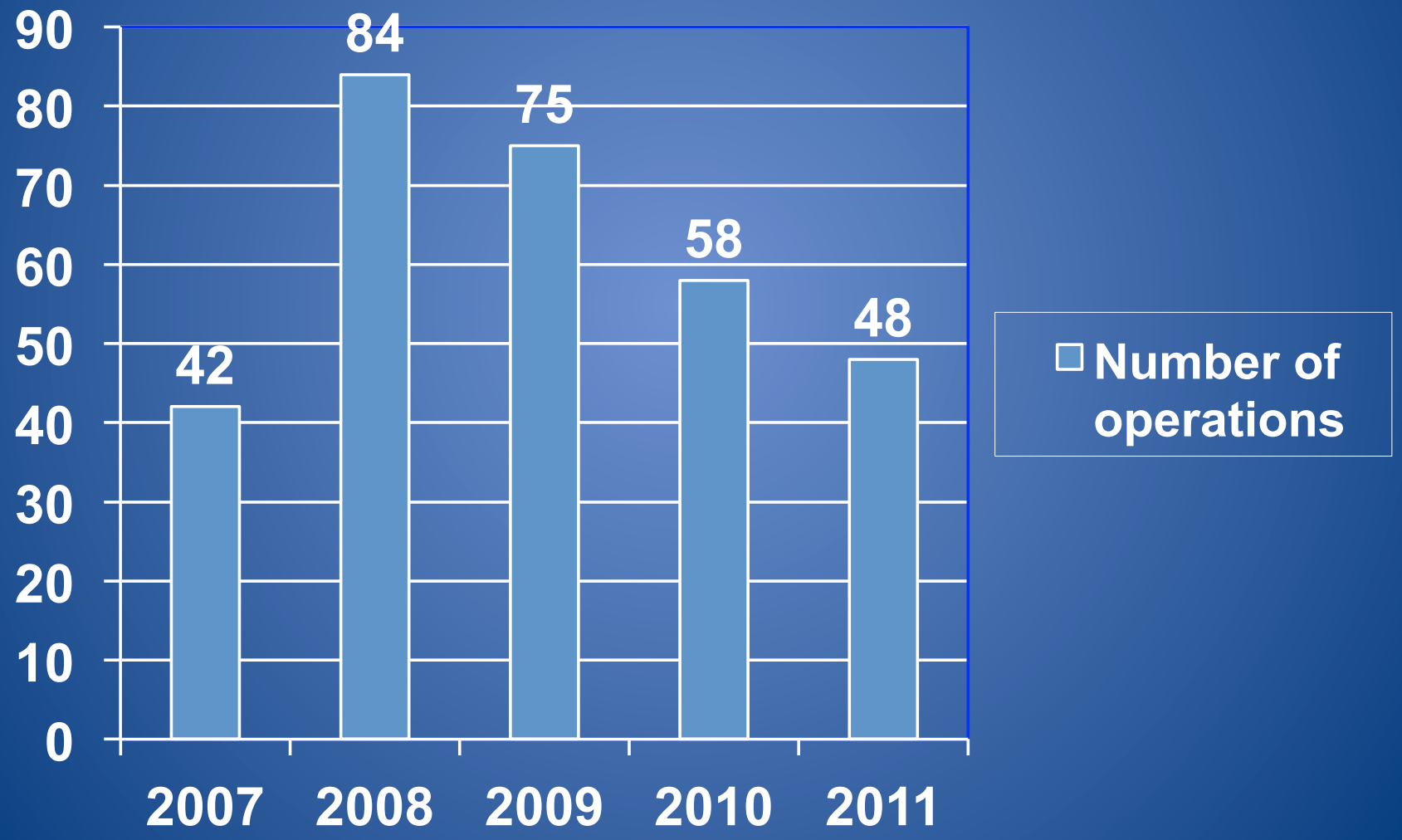

Kinds of endoscopic interventions (n= 309)

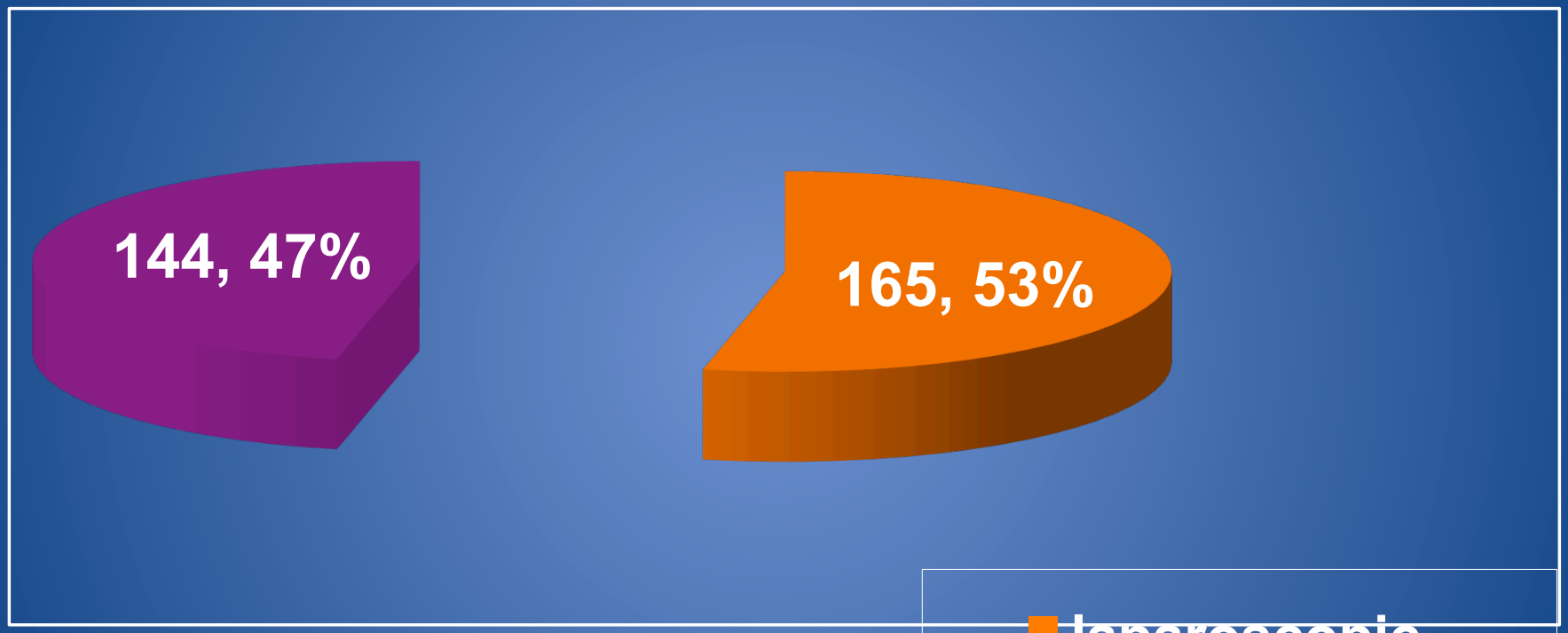

Age 3 weeks – 18 y (med 7.9y)
Time 28 min – 390 min (med 95 min)
Blood loss 10 ml – 1800 ml (med 120 ml)

Types of thoracoscopic interventions (n=144)

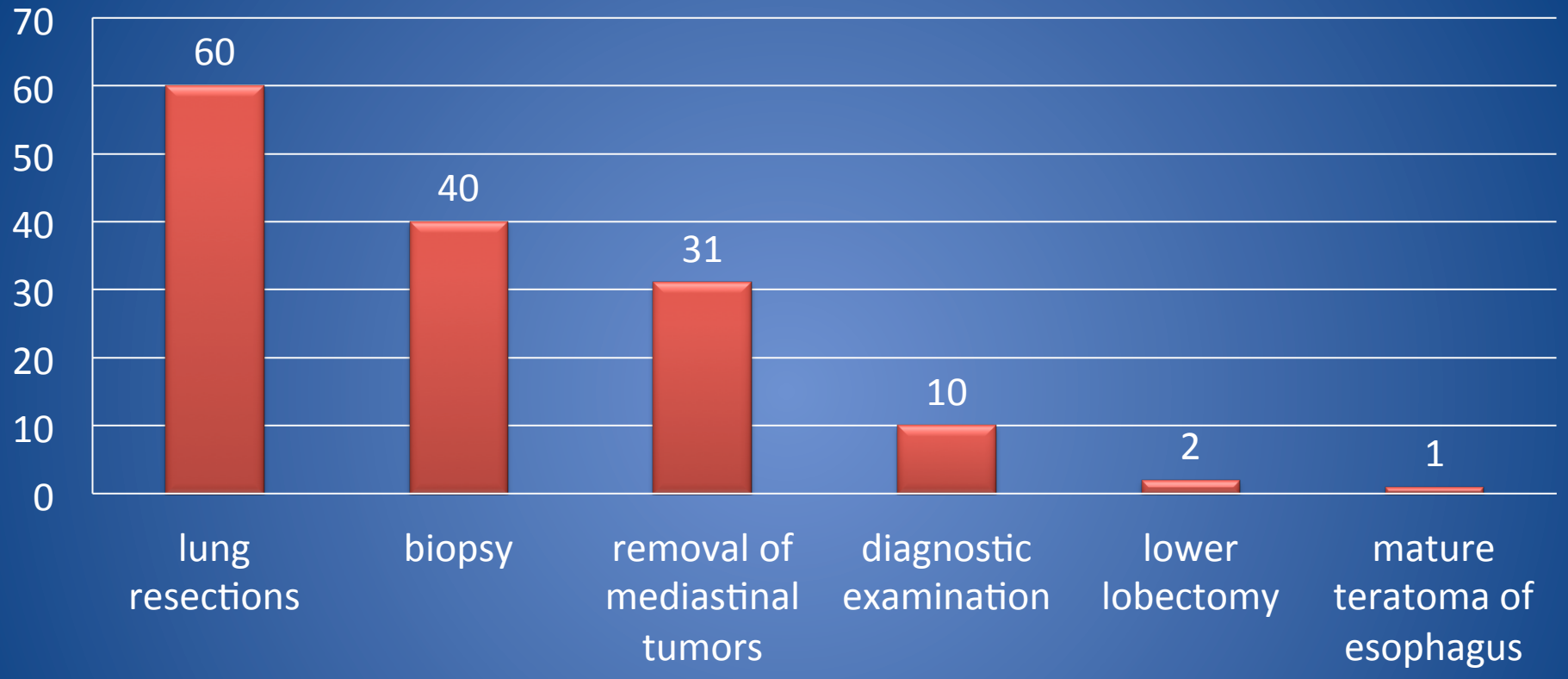

Types of laparoscopic interventions (n=165)

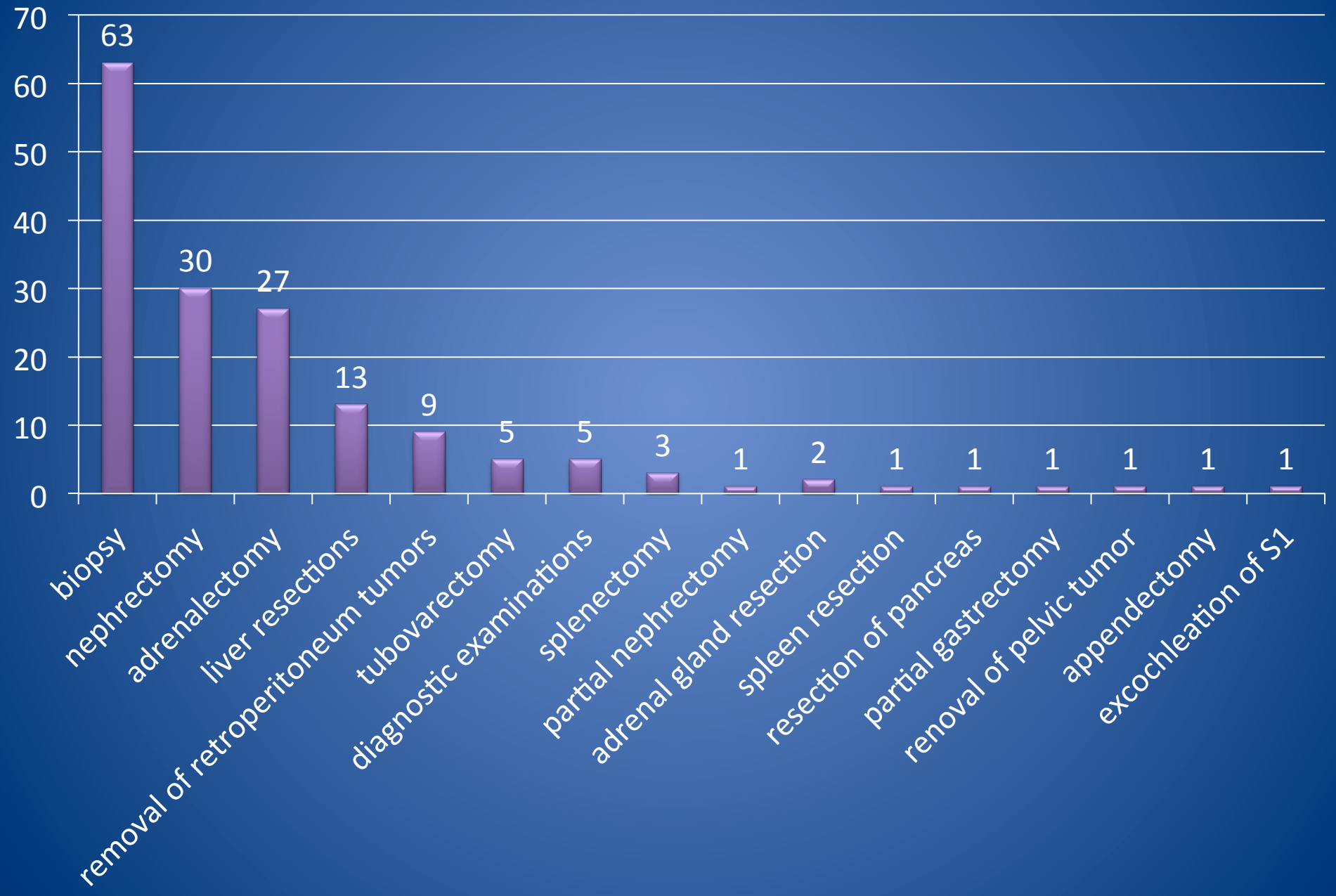

Hepatic resections (n=13)

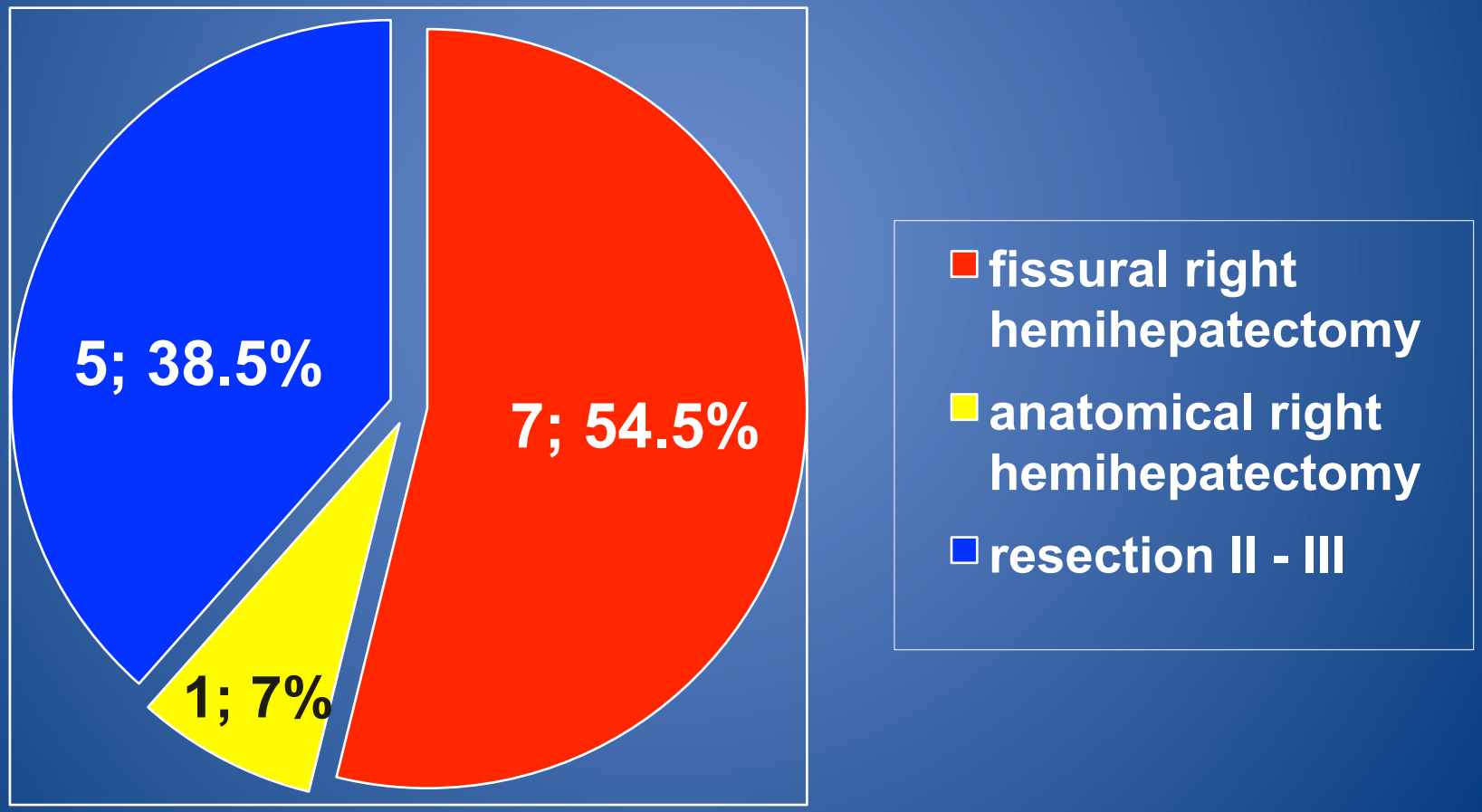

Case # 1: 2.5 y.o. male

Diagnosis: Hepatoblastoma. 3 courses of chemotherapy (SIOPEL 2, high risk), POSTEXT II. Tumor shrinkage – 80%

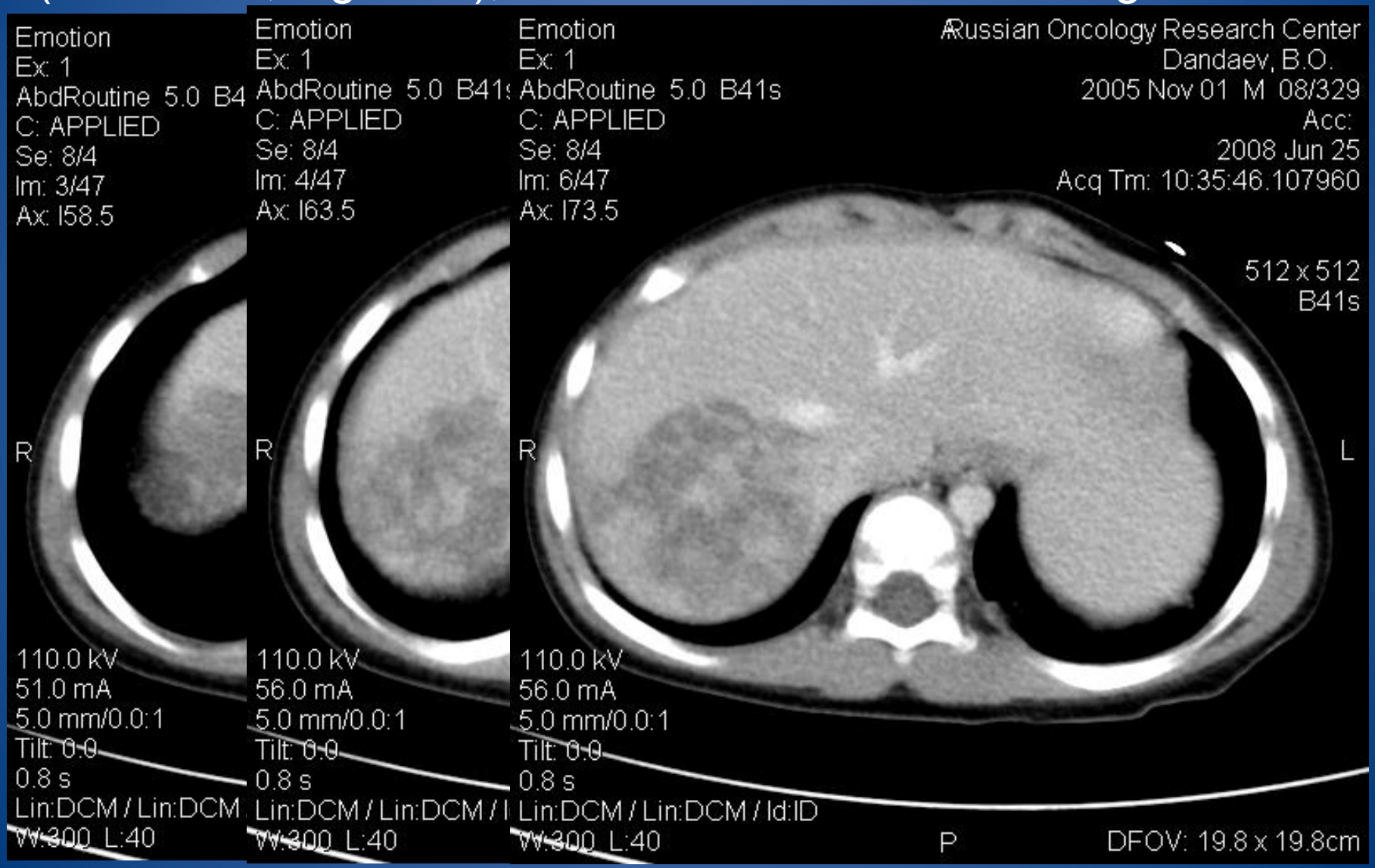

In 2008 y

- Laparoscopic right hemihepatectomy
- Blood loss 90 ml
- Duration 240 min
- ICU stay - 2 days

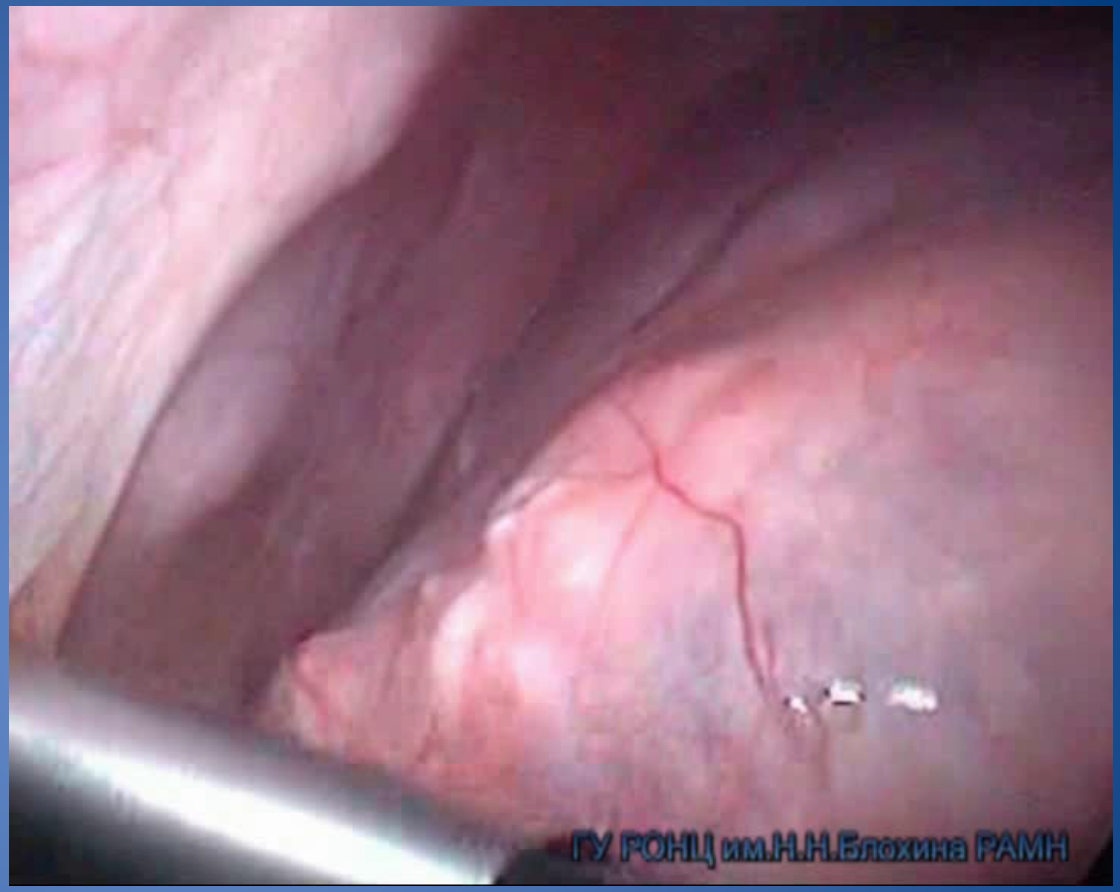

The foto of the patient on the 1st day after operation

- Antibiotics for 3 days post surgery
- Drainage was removed on the 2nd day after surgery
- The chemotherapy was begun on the 7th day

The combined using endosurgery and conventional surgery (n=3)

Localizations:

- Posterior mediastinum tumors with the spread to the retroperitonel space
- Tumors of aperture with the spread on the neck
- Tumors of anterior mediastinum crossing the midline

Case # 2:

4 y.o. male.

Diagnosis: neuroblastoma of aperture with the spread on the neck

Pathology: Mixed variant of ganlioneuroblastoma. No N-myc amplification.

No radiological response after chemo, but positive MIBG response.

Operation time (two stages) - 300 min

Blood loss – 100 ml

Drainages were removed on 2nd day

Horner's syndrome: no change

The combination of conventional surgery and videosurgery allows to optimise operations and to avoid thoraco- or laparotomy

Complications (n=16/309) and Conversions (n=6)

Complications	Number	Conversions or reoperations
Bleeding	7	6 **(aorta, suprarenal vena, IVC, SVC, liver)**
Eventration	4	**Closure of the defect in the aponeurosis**
Postoperative pancreatitis	3	**Choledocheal stricture, hepaticoejunostomy**
Ureteral injury	1	**Nephrectomy in 2 months**
Crossing of iliac vessels	1	**Prosthetic of iliac artery**

Disease progression (2 cases)

- In 6 months after liver resection (multifocal tumor at presentation)
- In 9 months local relapse in retroteritoneal space of malignant shwannoma

INDICATIONS FOR ENDOSURGERY

1. Nephroblastoma – *Stage I, without cystic components in the tumor*
2. Hepatoblastoma – *PRETEXT I, POSTEXT I/II*
3. Neuroblastoma – *depends on localization and ratio of cavity size and the size of the tumor*

(What exact criteria? Personal experience?)

Endosurgery can develop successfully in case of:

In accordance with oncological principles

Surgeons at any stage of operation should be ready for conversion

Videosurgical interventions should be carried out in clinics having sufficient experience of conventional surgery